



# ASSIST

MAGAZINE

Innovative Interventional Treatments

A photograph of a medical procedure in a catheterization laboratory. A patient is lying on a table, partially covered with a blue drape. A large, white, curved C-arm X-ray machine is positioned over the patient. A person in blue scrubs and a surgical cap is standing next to the machine, adjusting it. The room is brightly lit with overhead surgical lights. A monitor on the left shows various medical data and a GE logo.

## *Breakthrough in Image Guided Therapies*

TECHNOLOGY AT OUR  
FINGERTIPS WITH ALLIA

NEW SOLUTIONS FOR STENT  
ENHANCEMENT IN COMPLEX CASES



**Cecilia Felix**  
Image Guided Therapies  
General Manager  
EMEA Mature Markets



**Charline Chondrou**  
Digital Education Leader  
Interventional  
EMEA

*Dear Reader,*

*During these turbulent times, the only constant is your dedication to treating patients and the steady advancement of technology by your side. You are taking on more and more complex cases which require your complete focus on the patient and what we can do for you is relieve you from the surrounding complexities and allow you to have solutions at your fingertips.*

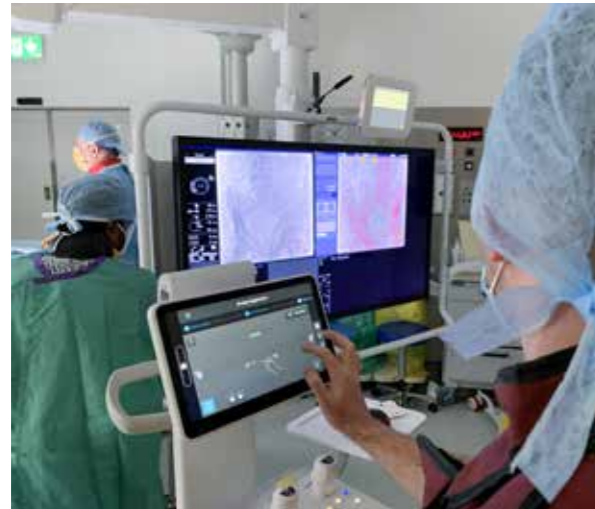*In this edition of the ASSIST magazine, we get to see what is essential to the teams working in our hybrid rooms and cathlabs around the world: providing reliability and lifelong support in challenging conditions, obtaining the optimal combination of image quality and dose with AI, creating an environment for the team to grow and surpass its limits.*

*In return, they share with us challenging cases with beautiful clinical outcomes some of which are in this magazine. You will read about minimally invasive vascular procedures and lung nodule biopsies taking place in hybrid rooms using cone-beam CT, advanced visualisation techniques and fusion as well as PCI procedures using IVUS - OCT - angiography coregistration and the latest stent visualisation tools.*

*We would like to thank our clinical partners for this amazing collaboration and wish you a good reading!*

*Cecilia Felix and Charline Chondrou*

# ASSIST MAGAZINE



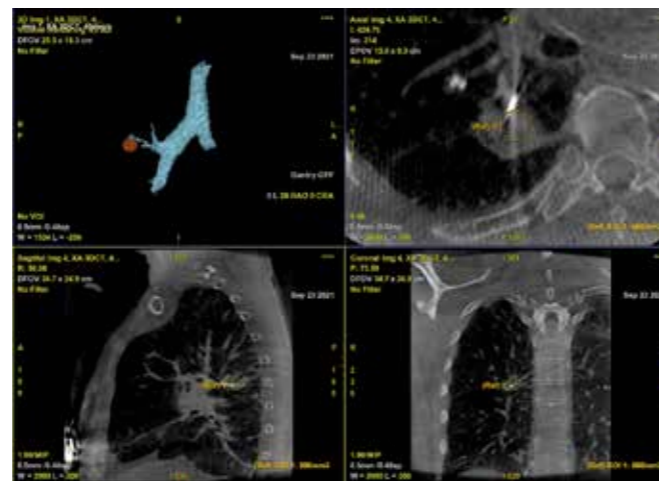
## 06\_ Vascular surgery: Technology at our fingertips

06\_ The first Allia IGS 7 hybrid OR lab in Europe

12\_ Case report: Percutaneous aorto-iliac revascularisation on Allia IGS 7 OR

14\_ Treating the whole spectrum of vascular diseases in a Discovery IGS 7 hybrid room

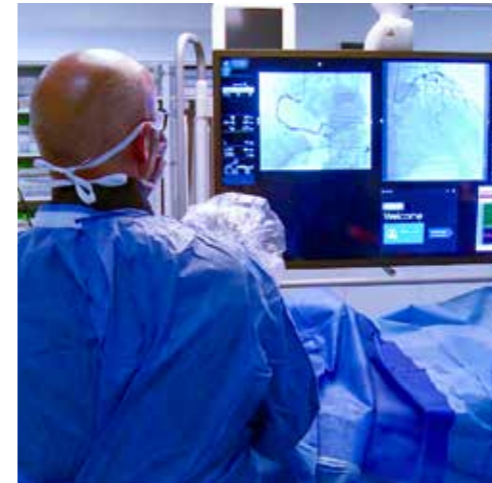
20\_ Case report: Saving limbs



## 22\_ Advanced imaging techniques in pulmonology

22\_ What can a hybrid room offer to the field of pulmonology?

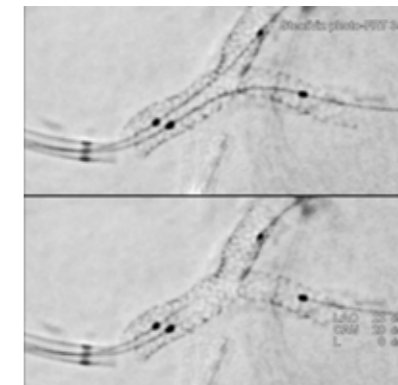
28\_ Case report: Lung biopsy using CBCT-based planning and guidance



## 30\_ Cathlabs maximizing efficiency

30\_ The cathlab that covers a third of Scotland with the latest Innova IGS 5 with AutoRight™

36\_ Exceeding expectations during a pandemic



## 46\_ Stent visualisation techniques for PCI

46\_ Leveraging technology for complex PCI procedures

50\_ Case report: StentViz for accurate bifurcation stenting

### Local Contact Information:

GE Healthcare Buc  
283, rue de la Minière  
78533, Buc Cedex, France

Chief Editor: Charline Chondrou

Editorial Team: Barnabas Nagy, Ioané Cartier, Dustin Boutboul, Eleonora Viviani, Catherine Beignon, Emmanuelle Majus, Cameron Ferguson, Mathilde Dauchez, Renata Reveco

Design: Nathalie Ollivier

Printer: Groupe Lecaux Imprimeries HandiPRINT

### Many thanks to our contributors :

- Prof. Stewart Walsh, UK
- Prof. Muhammad Tubassam, UK
- Dr. Mahmoud Alawy, UK
- Eamonn Coffey, UK
- Dr. Theodosios Bisdas, GR
- Dr. Nicola Facciolo, IT
- Dr. Roberto Piro, IT
- Prof. Steve Leslie, UK
- Dr. Jonathan Watt, UK
- Rebecca MacLeod, UK
- Prof. Béla Merkely, HU
- Dr. István Édes, HU
- Dr. Balázs Németh, HU
- Dr. Krisztina Heltai, HU
- Szilvia Szabó, HU
- Dr. Bruno Farah, FR

# The first Allia IGS 7 hybrid OR lab in Europe

Galway University Hospital is one of the largest hospitals in the west of Ireland, catching about 1 million people from Donegal down to County Clare. The vascular department is a tertiary centre for vascular diseases. They have around 100 aneurysm treatments per year, including elective and ruptured aneurysms.



**Prof. Stewart Walsh**

is the Professor of Vascular Surgery at NUI Galway. He has published almost 200 articles, commentaries and letters in peer-reviewed journals. He has edited two books (General Surgery Outpatient Decisions, 2nd Ed, Radcliffe, 2008 and Cracking the Intercollegiate General Surgery FRCS, Taylor & Francis 2014) and is a contributor to the Oxford Handbook of Clinical Surgery. He has extensive experience in clinical comparative-effectiveness research both as principal investigator in clinical trials as well as leading teams undertaking systematic reviews of both test accuracy and interventions.



**Eamonn Coffey** is the Clinical Specialist Radiographer in the hybrid lab of Galway University Hospital.



**Prof. Muhammad Tubassam**

has been working as a Vascular and Endovascular Consultant Surgeon at University College Hospital Galway, since 2010 and has his own private practice at the Galway Clinic. He is a participating consultant and is interested in the entire spectrum of Vascular Diseases with a particular emphasis on Aortic Aneurysmal Disease, Carotid, Peripheral Vascular Disease and Varicose Veins.



**Dr. Mahmoud Alawy**

is a consultant Vascular Surgeon. He has a special interest in minimally invasive surgery techniques to treat aneurysms and other aortic problems. He published research on aortic aneurysm, carotid surgery, vascular access and peripheral vascular disease.

**What were the main challenges with your previous imaging system?**

**MA:** we had a C-arm previously and unfortunately, we couldn't perform many complex interventions, such as complex branching or fenestrations, or arch interventions. We needed advanced guidance like fusion imaging or Cone Beam CT, which Allia IGS 7 OR\* provides now.

*"For me, the Allia IGS 7 OR is a game changer."*

**MT:** The challenge with the C-arm was the amount of radiation exposure and the amount of dye that we had to use for complex aneurysms and peripheral vascular disease. It was also breaking frequently. With the way technology is

changing, and the way the aneurysm pathology is changing, we couldn't do any more complex cases with the C-arm. With Allia IGS 7 OR, rather than referring these patients to another hospital, facing long waiting lists, we can now offer those interventions in our own hospital.

**EC:** The C-arm had to be moved all the time to cover a long lesion, whereas we get the full field of view all in one shot with the large detector and it really does improve the patient pathway throughout the case.

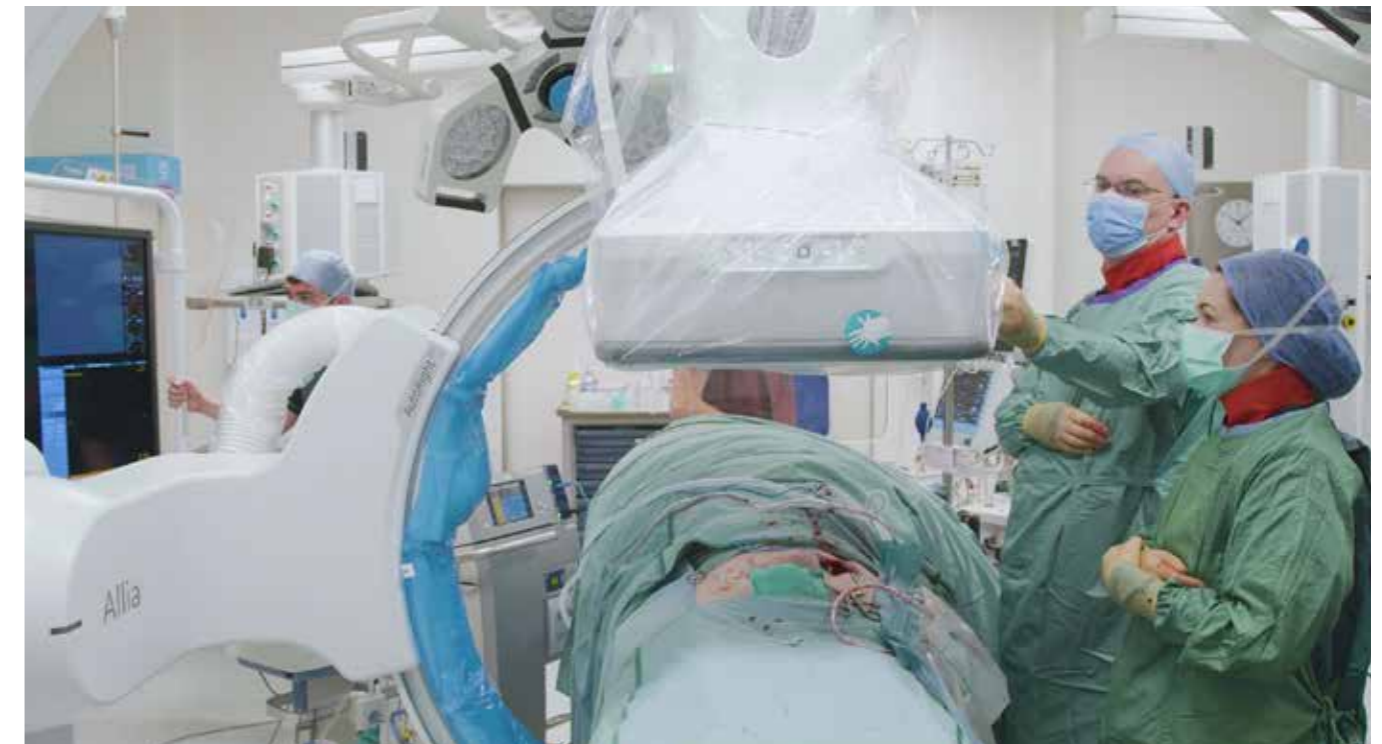**How did Allia IGS 7 OR change your daily practice?**

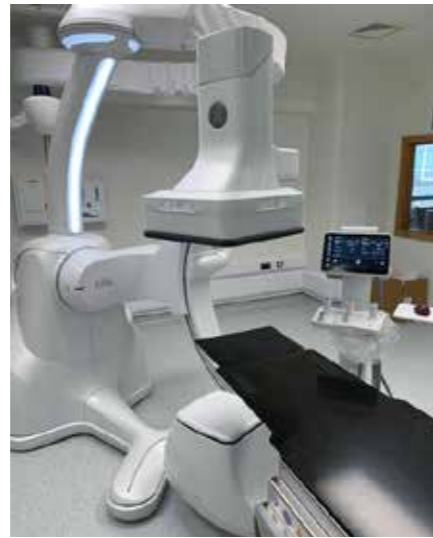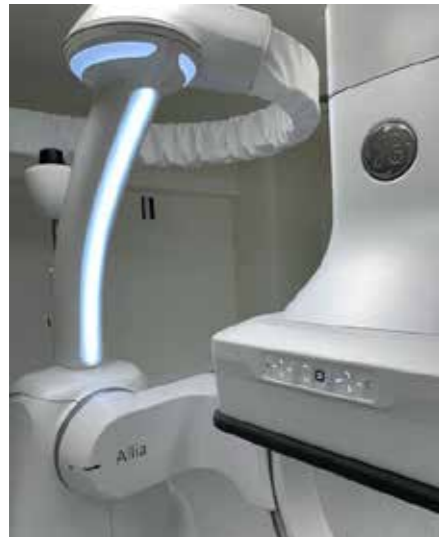**SW:** The fusion imaging, with CT overlay on live fluoroscopy, makes a big difference. When you are doing a subintimal angioplasty, particularly in a patient who doesn't have a huge amount of calcium in the vessel walls,

it's hard to know if you are staying in the path of the artery or not. When you plan targets on the CT and fuse them with fluoroscopy, it is actually very easy to see where to head for. On top of that, a lot of the features are helping us to reduce the contrast load for the patients and reduce the operative time. It's an excellent system, we're very happy with it.

**MA:** The radiation exposure with the Allia system is managed by AutoRight™1 so the right dose for the right patient at the right time is delivered. This reduces the radiation exposure for ourselves and for the patient as well.

**MT:** it's night and day compared to the C-arm. With Allia IGS 7 OR I'm able to do most of my aneurysm work at 7.5 frames per second only. We have the fusion technology which shows us





**MA:** I feel in control of the dose the system is delivering. With the AutoRight™<sup>1</sup> cockpit on the live screen, you have everything in front of you and you don't need to ask around or worry about going beyond the set thresholds.

**EC:** As a radiographer, it is my role to always look out for the radiation dose and trying to reduce it. The live dose information is displayed in such a user-friendly manner that it helps decide if there is room to reduce the dose and still produce an acceptable image.

**How do you think the Allia IGS 7 OR system can improve patient outcomes?**

**SW:** I think the main impact is going to be reduced numbers of patients coming back for repeat procedures. For example, I recently treated a patient with bilateral SFA occlusions. If we didn't have the Allia IGS 7 OR system in place, I would have probably done the first leg on one day with a C-arm and the other leg another day. He would have stayed in hospital for a week and he would have been occupying a bed, so I think we'll see increased throughput that will reduce patient length of stay.

**MA:** First of all, the patient throughput should be improved so it will help reducing the waiting list. Secondly, thanks to the pre-procedure planning it is possible to decrease the radiation dose. By fusing the planning to the live screen and recalling the saved angles without repeating runs, we save time, radiation and contrast.

**EC:** We did a lower limb case recently, that would have taken three to four hours previously.

With the Allia IGS 7 OR it was done in less than two hours and it was less invasive. This is also beneficial for the patient recovery time to have the shortest intervention possible.

**Compared to other systems you might have worked with in the past, what do you feel will be the biggest difference with Allia IGS 7 OR?**

**MT:** The biggest improvement for me is the ease of use. It's not ceiling mounted, it is not floor mounted, it doesn't occupy any space at all, there is no collision with the different instruments in the theatre. We are able

to use our two large display monitors on both sides of the table and the injector as well.

**EC:** I was so pleasantly surprised with the quality of the images. Even with the lowest dose, the image quality seems to be phenomenal, and it seems to be the optimum image for the patient.

*"You have everything you need within your reach and it improves the flow of the procedure."*

**SW:** it allows us to take on more complex cases. We are more comfortable with having a fixed imaging system compared to some of the challenges of the mobile C-arm linked to the case duration. With the fusion technology, we are able to operate with far less runs than we have previously been used to, therefore reduce the radiation dose. □

exactly where the arteries are on the patient CT. Thanks to this, we use the minimum dose of contrast to prevent any kidney damage. I'm a consultant who started as a trainee when only open procedures were performed. Then we moved towards the angioplasty and the C-arm. For me, the Allia IGS 7 OR is a game changer.

**What do you think about the positioning of the system?**

**MA:** I appreciate it when I don't need to search where the table and gantry controls are during a procedure. It's very handy to have both of them accessible on the detector while you do surgery. You have everything you need within your reach and it improves the flow of the procedure.

**SW:** The ergonomics of the Allia system are excellent. It flows much more smoothly than it would traditionally have been the case when we were using a mobile C-arm.

Although the hybrid lab is full of people and equipment, we manage to position the Allia IGS 7 OR comfortably. We

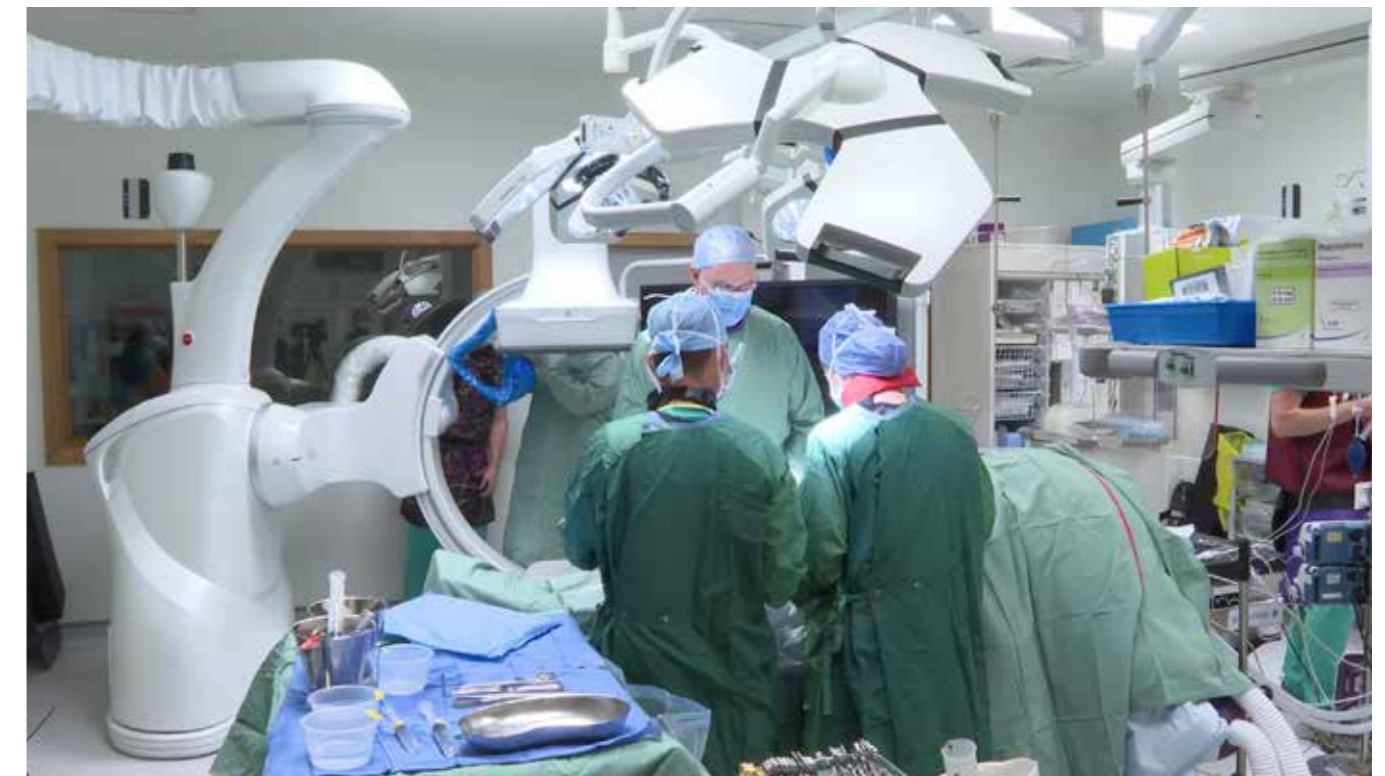have much better movement on the Maquet Magnus OR Table compared to our previous table. My advice is to discuss in advance with the team, in particular the anaesthetic team to have the patient in the most appropriate position prior to every procedure.

**How do the Allia profiles help your practice?**

**MT:** Rather than telling the radiographer for every procedure that I need specific settings, they are already saved in the system. The radiographer only has to select the corresponding profile with one click.

**EC:** I think the user profiles will save a lot of time and prevent a lot of confusion in the long run. The consultants have different imaging preferences depending on the type of procedures (aortic, lower limbs, etc...). It's easy to get the profiles ready for them.

**What are the benefits with using the AutoRight™<sup>1</sup> cockpit display of the dose rate?**



The statements by GE's customers described here are based on their own opinions and on results that were achieved in the customer's unique setting. Since there is no "typical" hospital and many variables exist, i.e. hospital size, case mix, etc., there can be no guarantee that other customers will achieve the same results.

\*Allia IGS 7 OR, configuration 740

1 AutoRight refers to intelligent image chain features of GEHC's Interventional x-ray systems, from image acquisition to image processing and display, available on Innova IGS 5, Innova IGS 6, Discovery IGS 7, Discovery IGS 7 OR, Allia IGS 7 and Allia IGS 7 OR

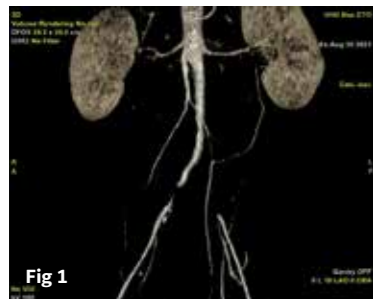# Percutaneous aorto-iliac revascularisation on Allia IGS 7 OR

Courtesy of Dr. Alawy, vascular and endovascular surgeon, Galway University Hospital

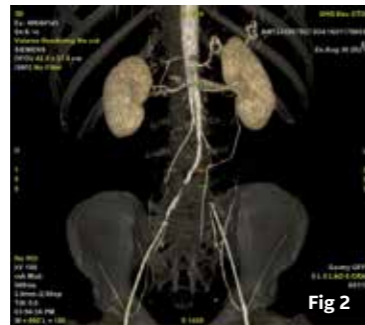
## Patient History

52-year-old male. Presented with claudication at 20 yards (~18m). Weak right femoral pulse only.

CTA shows 60-70% stenosis in aorta, concentric thrombus originating just below renal arteries. Left iliac completely occluded. Right side thrombosed with only trace of contrast (Fig. 1).



I then selectively placed further planning lines through the occluded left iliac artery to aid guidewire advancement and at the most stenosed point in the right iliac artery (Fig. 2).

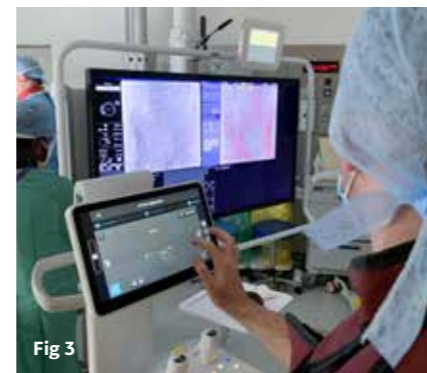

## Procedure

AGV placed in parking position to enable unobstructed access to the patient. Bilateral U/S-guided punctures, with eventual left-sided cutdown, was used to obtain vascular access. A Large Display Monitor configuration was used to show U/S imaging.

Acquisition parameters: DSA Level 2; Fluoro @ 7.5fps, Level 2 with Dose Limiter active.

Bi-view registration was quickly and efficiently undertaken by Eamonn Coffey (Clinical Specialist Radiographer) at tableside with touchpad using LAO/RAO fluoro images matched to the 3D bone volume (Fig. 3).



Once registration was complete, the vascular outline model was used showing specific points of interest highlighted by planning lines.

A retrograde cannulation of the occluded left iliac proved unsuccessful through the left groin sheath. An approach "up and over" the aortic bifurcation from the right

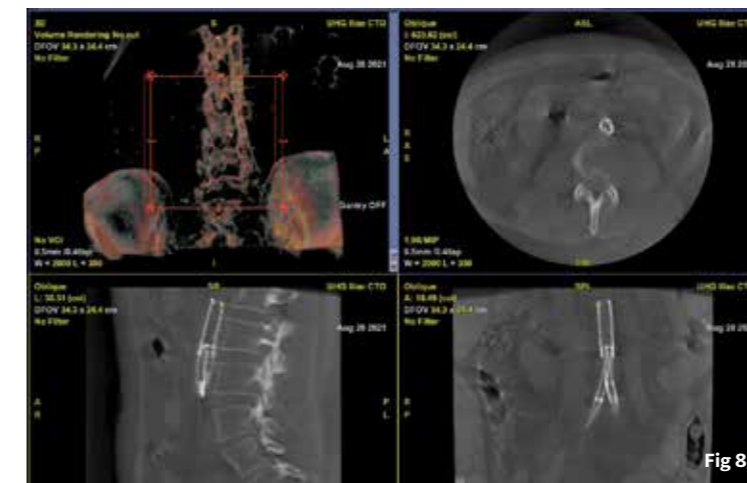
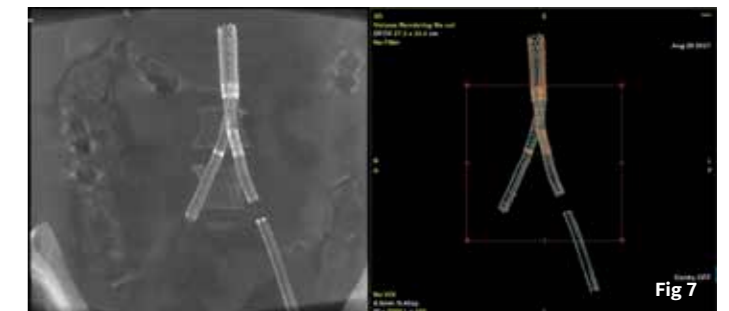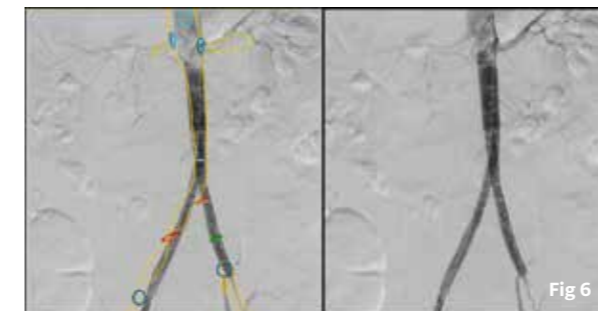
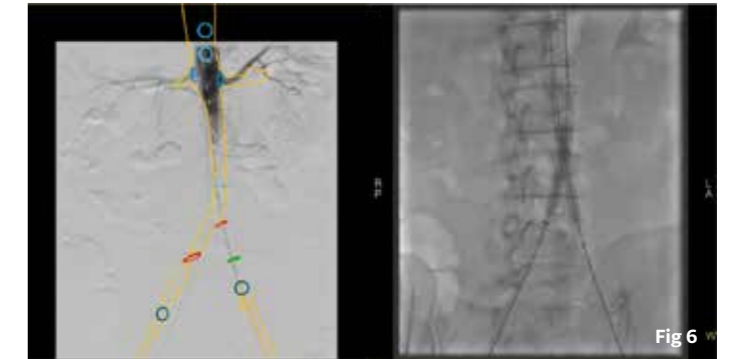
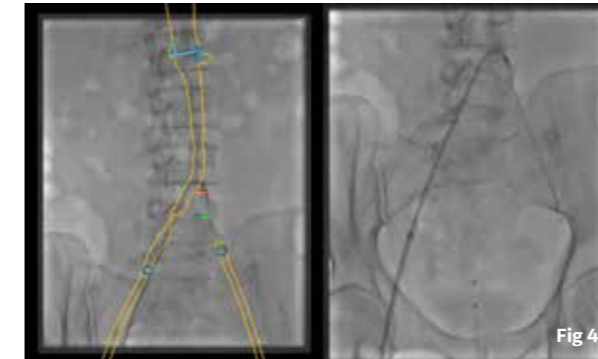
arteries was guided by 3D model guidance, which after minor dynamic registration adjustment following a single DSA, allowed accurate deployment (Fig. 5).

Bilateral 8mm x 59mm stent grafts were deployed from the aorta into the iliac arteries using landmarks placed on 3D model (Fig. 6).

A final 7mm x 100mm stent graft was placed in the left iliac artery. During

creation of the pre-op 3D model an optimal angle for deployment was identified and saved. This was recalled at tableside.

Completion DSA showed an excellent result. A final non-contrast CBCT (5s acquisition at 40degrees/s, dose level 4) demonstrated perfect expansion and overlap of the stent grafts with coverage from below the renal arteries to femoral artery (Fig. 7,8).



## Plan

Percutaneous aorto-iliac revascularisation. If passing the guidewire through the diseased sections is unsuccessful, resort to traditional open surgical bypass technique.

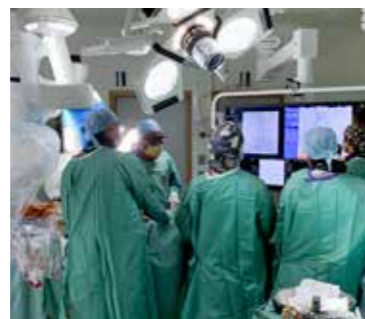## Preparation

Using Vessel ASSIST<sup>1</sup>, I created 3D models of the patient's vascular anatomy to guide the procedure and bony structures to facilitate bi-view registration, using automatic bone removal and vessel segmentation.

Planning lines were placed at the ostia of bilateral renal and internal iliac arteries.

## Theatre Setup

Using the X-ray tabletop of the Allia IGS 7 OR, the patient was placed headfirst with the AGV\* at 90 degrees. This allowed easy access to the patient's head for anaesthetists and surgeons to work from both sides of the patient whilst gaining vascular access. This setup also allowed the AGV to be moved along its panning trajectories minimising the need to move the table.



Dose Measurements	
Screening time	47:10mins
Dose	422mGy
DAP	132.43Gycm2

The statements by GE's customers described here are based on their own opinions and on results that were achieved in the customer's unique setting. Since there is no "typical" hospital and many variables exist, i.e. hospital size, case mix, etc., there can be no guarantee that other customers will achieve the same results.

\*AGV (Advanced Guided Vehicle)

1 Vessel ASSIST solution includes Vision 2, VessellQ Xpress, Autobone Xpress and requires AW workstation with Volume Viewer, Volume Viewer Innova. These applications are sold separately.



## Treating the whole spectrum of vascular diseases in a Discovery IGS 7 hybrid room

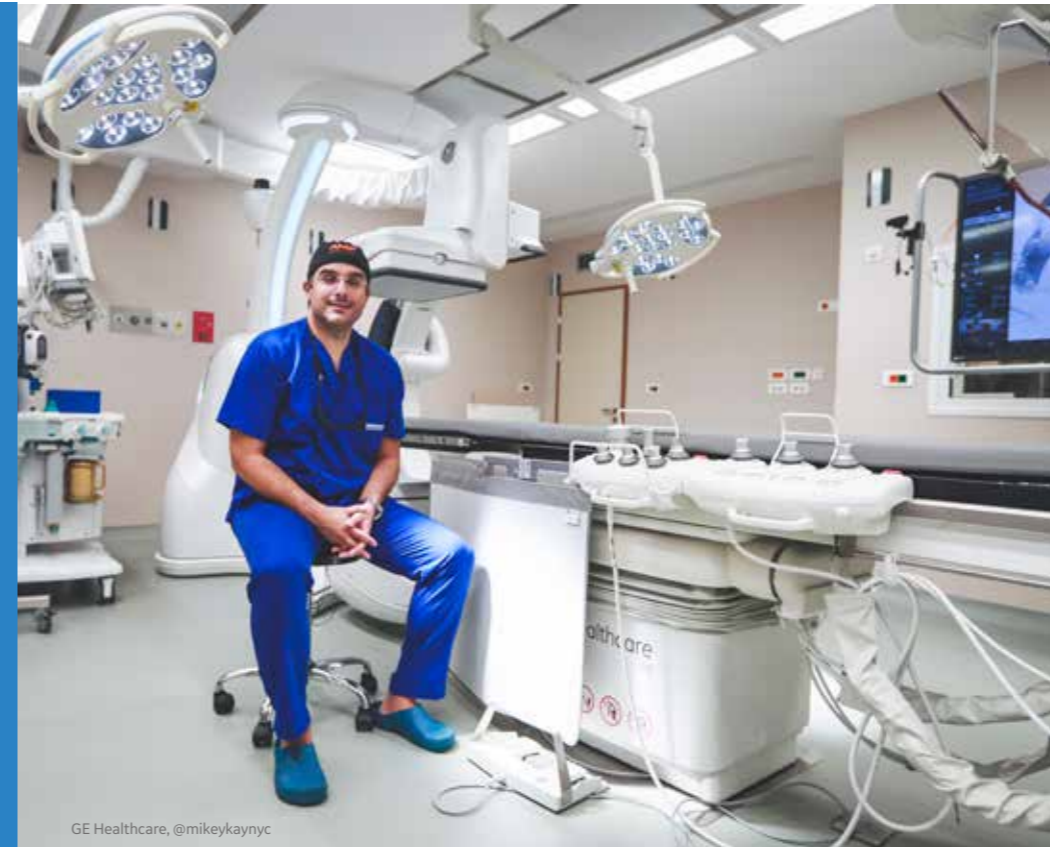Athens Medical Group (AMG) was founded in 1984 by Dr. G. Apostolopoulos with the vision to stop the flow of Greek patients to medical destinations in Western Europe and the USA. Today, AMG is a top-level Health Care Group, whose hospitals operate under the strictest international quality criteria, collaborating with highly specialised and experienced medical and nursing personnel and constantly investing in state-of-the-art medical equipment. AMG's mission is to offer top quality, patient-centric health care services. The Group currently runs 8 ultramodern hospitals with a total capacity of 1,200 patient beds and collaborates with more than 2,800 highly qualified physicians of all specialties, with international experience. It employs more than 3,000 full time employees and it cooperates with the most eminent Universities and Organizations in the world.





Dr. Theodosios Bidas is an Associate Professor for Vascular Surgery and an endovascular specialist, certified by the German Society of Vascular Surgery and Medicine. He is Chief of Vascular Surgery at the Athens Medical Group with special clinical and research interest in complex aneurysms, critical limb ischemia and deep vein thrombosis. Dr. Bidas has more than 130 publications in peer-reviewed journals (h-index: 29), he belongs to the Editorial Board of several journals and he serves as a reviewer in more than 20 journals. He has received several national and international awards. In 2015, he received the Vascular Career Advancement Award in Las Vegas, USA. He belongs to the

advisory board of several companies and he is the founder of the e-learning platform Vascupedia.



GE Healthcare, @mikeykaynyc

The “Promitheas” hybrid OR was built in 2019 in the Athens Medical Center, a leading private hospital in Greece and was dedicated to the multidisciplinary treatment of cardiovascular diseases. The operation room is equipped with the Discovery IGS 7 angiographic system from GEHC, which enables the minimally invasive or hybrid repair of all vascular territories with its unique technical characteristics as well as the ASSIST solutions<sup>1</sup>. Within the last 2 years, more than 700 interventions from vascular surgeons, cardiologists, interventional radiologists and cardiac surgeons were performed

**What were your criteria for selecting the Discovery IGS 7\* system to work on?**

The Discovery IGS 7 provides the ideal environment for safe and effective interventions in all territories of vascular surgery. The safety is due to the ergonomics of the system, the stringent hygiene standards and the free space that it provides to the surgeon for elective or urgent hybrid procedures. On the other hand, the effectiveness is due to the unique features of the Discovery IGS 7 including the ASSIST solutions<sup>1</sup> and the 3D CT HD<sup>2</sup>, which decrease operation time, radiation and iodine dose and optimize the final outcome.

**How many teams work in the hybrid room?**

The hybrid room is mainly focused on cardiovascular interventions. Consequently, vascular surgeons, cardiac surgeons, cardiologists and neuroradiologists are working in this room. However, there have been also some cases of multidisciplinary work between vascular and general surgeons as well as thoracic surgeons and pulmonologists.

**What were the difficulties when setting this new hybrid room up? How long did it take for things to fall into place and your team members to collaborate in a seamless way?**

All involved surgical teams were very confident with the use of the new hybrid room directly from day 1. The main challenge that we faced was to place all persons and devices needed for complex interventions in the right and most comfortable position for them. After the first interventions, all physicians (interventionalist, anesthetist, nurses etc.) and devices (CO2 injector, contrast agent injector, surgical tools etc.) found their place and role in the room.

**What aspects of your work are now done in a more efficient and easy way in a hybrid room? Are there some aspects that became more complicated?**

Several aspects of our daily practice have been improved and optimized in the new hybrid room. First of all, the wide bore C-arm, the large detector and the large screen are very helpful in complex procedures. The long bed is very important for securing long wires and catheters from falling down. The operators are feeling more confident to perform open surgical procedures parallel to the endovascular interventions for complex vascular disorders. Moreover, the anesthetist has more space for safe intubations and monitoring of the patients. Finally, the ability of intraoperative 3D CT HD<sup>2</sup> reduced significantly the rate of complications and reinterventions.

**What procedures do you do in your hybrid room?**

Our spectrum includes treatment of all vascular diseases from carotid artery to small toes of the forefoot. In the arterial circulation, we perform carotid artery stenting, angioplasty of the supraaortic arteries, endovascular repair of complex aortic diseases (aneurysms, dissections or occlusions), endovascular or hybrid repair of the infringuinal/infrapopliteal arteries in patients with peripheral arterial disease and minimally-invasive treatment of visceral artery aneurysms or stenoses. With regards to the venous circulation, we are treating by endovascular means patients with



GE Healthcare, @mikeykaynyc

acute and chronic deep vein thrombosis as well as pulmonary embolism.

**A hybrid room usually comes with a more hands-on mentality for a vascular surgeon compared to working in an operating** ...

**theatre and not interacting much with the equipment. This was not the case for you, but how steep is the learning curve in your opinion for someone who transitions from theatre to hybrid OR?**

The transition for a vascular surgeon from theatre to hybrid OR is surely an amazing experience considering all the comfort and technological aspects that the Discovery IGS 7 system offers. There is not really any learning curve for such a transition. The most important issue remains the support from the manufacturer in order for the operator to understand all the possibilities and options that are available.

**An interventional system and everything that comes with it obviously takes up more space than a mobile C-arm. Is the flexibility of the Discovery IGS 7 making up for this and allowing you to obtain any setup required to do your job or not?**

It is true that the Discovery IGS 7 takes more space compared to a mobile C-arm but the automation of certain functions, the mobility of the device and the flexibility make your practice easy in all different setups. However, my advice to all future users is to select if possible hybrid rooms with an area larger than 80 to 100 m<sup>2</sup>. Especially in complex cases where you need long tables for concomitant transfemoral and transbrachial approach, the existence of a large room is essential.

**Do you use any other imaging technique aside from X-rays when you are in the hybrid room?**

I am always using ultrasound-guided puncture to create access for my interventions via the femoral or the brachial artery. Moreover, the ultrasound is used for retrograde access (through the tibial arteries) in case of complex interventions in patients with peripheral arterial disease and at the end of the procedure

in order to assess the blood flow to the forefoot. Last but not least, I am always using intravascular ultrasound for venous interventions (thrombectomy of the iliac veins and stenting).

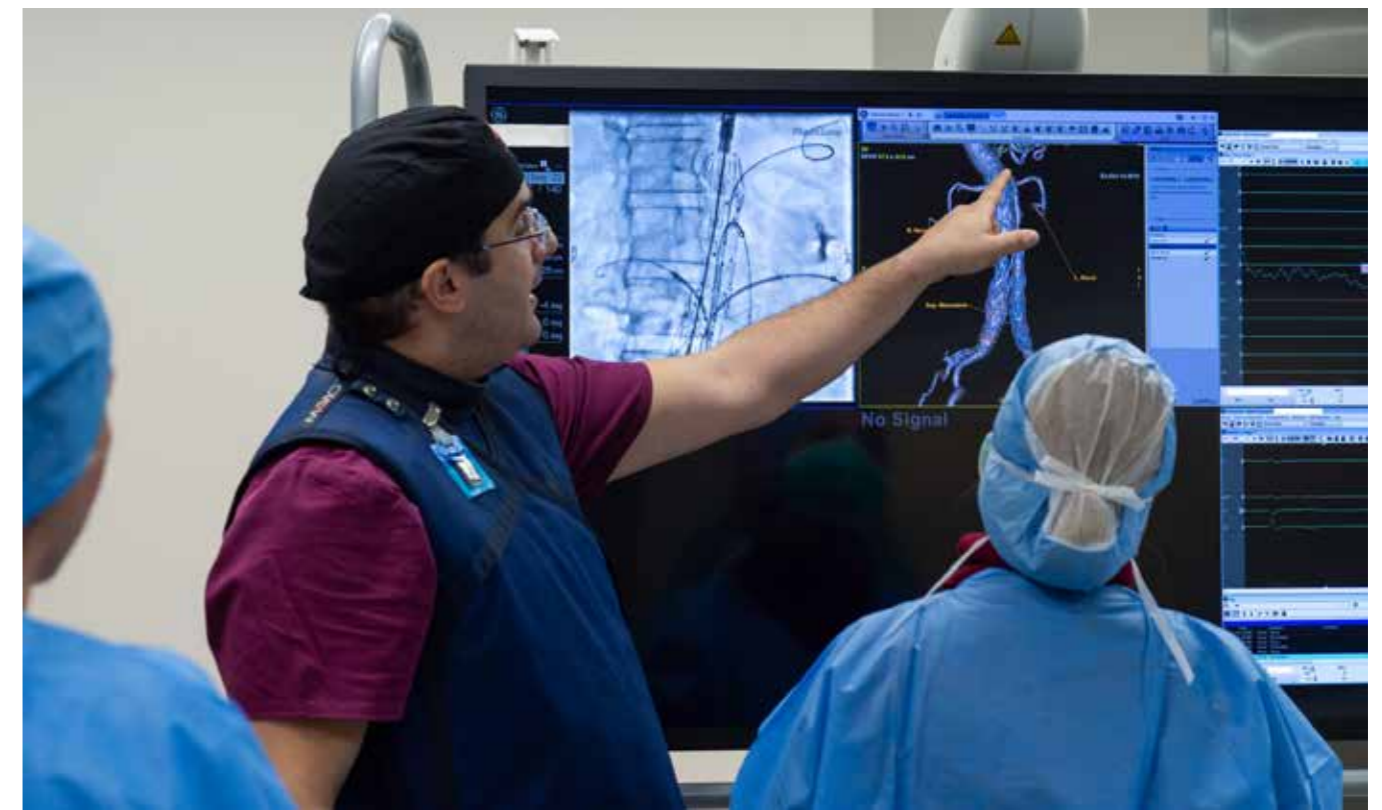**When working on EVAR procedures, do you use EVAR ASSIST 2<sup>3</sup>? If so, what do you gain from the planning and guidance tools?**

I am always using EVAR ASSIST 2<sup>3</sup> from the most simple to the most complex endovascular aortic repair. There are several reasons for this strategy: (1) less radiation exposure for both operator and patients, (2) less contrast agent, (3) better guidance of guidewires and devices through the aorta and finally (4) high-quality digital magnification without the need for more radiation. Moreover, the whole process of preparing the procedure with EVAR ASSIST 2<sup>3</sup> provides you with a more thorough overview of the anatomy, the challenges and the dimensions of the aneurysm.

**Do you use the AW server and has it turned out to be useful to you?**

The AW server is very comfortable for my daily practice. Using the planning workflow of EVAR ASSIST 2<sup>3</sup> I prepare the case and I perform the measurements in order to have all the models ready for fusion on the day of the intervention. Everything can be done from my office without the need to visit the hybrid room for case planning.

**When working on peripheral vascular diseases, which tools give you important information in order to assess the quality of the result?**

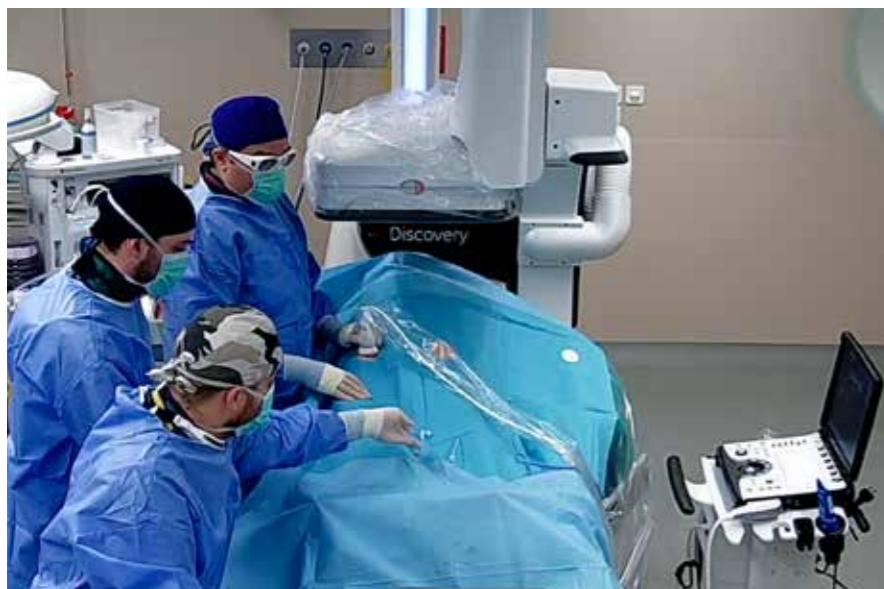

The Discovery IGS 7 provides two unique tools for peripheral interventions which facilitate the intervention and optimize the final outcome especially in the challenging scenario of critical limb ischemia and/or diabetic foot syndrome. The first feature is Vessel ASSIST<sup>4</sup>, which provides information about the anatomy of chronic total occlusions, guides the recanalization of the lesion and highlights all severely calcified lesions which need extensive vessel

preparation for adequate lumen gain. On the other hand, the system provides the unique tool of colour-break opacified images (AngioViz<sup>5</sup>) which demonstrate the changes in the perfusion of the forefoot prior to and after the revascularization. The latter is extremely helpful, although further research on standardizing thresholds is needed.

**What are the challenges for the diabetic foot procedures?**

The diabetics show severe atherosclerotic lesions in smaller vessels (microangiopathy) and the recanalization of these vessels below the knee and/or the ankle is very challenging. Moreover, after the revascularization, the foot requires thorough debridement and minor amputation or skin transplantation. In this context, the hybrid room is the ideal environment for such types of combined procedures. □



The statements by GE's customers described here are based on their own opinions and on results that were achieved in the customer's unique setting. Since there is no "typical" hospital and many variables exist, i.e. hospital size, case mix, etc., there can be no guarantee that other customers will achieve the same results.

\*Discovery IGS 7, configuration 740

- 1 ASSIST solutions are composed of multiple medical devices. For more information, please refer to GEHC's website. [www.gehealthcare.com/assist](http://www.gehealthcare.com/assist)
- 2 3D CT HD is an option sold separately. Includes 3DXR. Requires AW workstation and Volume Viewer. Available on Innova IGS 5, Innova IGS 6, Discovery IGS 7 and Discovery IGS 7 OR.
- 3 EVAR ASSIST 2 includes FlightPlan for EVAR CT, EVARVision, and requires AW workstation with Volume Viewer, Volume Viewer Innova, VesselIQ Xpress, Autobone Xpress. These applications are sold separately.
- 4 Vessel ASSIST solution includes Vision 2, VesselIQ Xpress and Autobone Xpress, and requires AW workstation with Volume Viewer and Volume Viewer Innova. These applications are sold separately.
- 5 AngioViz requires AW workstation. This application is sold separately.

# Saving limbs

Courtesy of Dr. Theodosios Bisdas, Athens Medical Center (Greece)

## Patient History

A 63-year-old female presented to our department with severe gangrene of the right forefoot (Fig 1). The patient suffered severe comorbidities including type 2 diabetes mellitus, coronary artery disease and end-stage renal disease. In the previous surgical history, the patient underwent a minor amputation of digits 3 to 5 and the metatarsal bones due to severe gangrene, without any revascularization of the infrapopliteal arteries. The wound did not heal and further gangrene was developed in the remaining toes and the heel.

## Ultrasound Examination

The ultrasound examination revealed occlusion of the anterior and posterior tibial arteries, high-grade stenosis of the fibular artery and patent posterior tibial artery below the ankle.

## The Procedure

The patient underwent a diagnostic angiography which confirmed the aforementioned findings. The recanalization of the peroneal artery and the angioplasty of an occluded branch which communicated with the inframalleolar part of the posterior tibial artery led to the improvement of the

forefoot perfusion. After the successful revascularization and the final DSA, a single colour-coded image of peak opacification of the forefoot was provided by AngioViz<sup>5</sup> (Fig 2) and showed a significant increase in the perfusion. This was the criterion to stop any further recanalization attempt. An extensive wound debridement and a minor amputation of the toes and the first two metatarsal bones was performed. The wound deficit was covered with autologous skin. In the 3 months follow-up the foot was completely healed and any major amputation was prevented. The patient was able to walk on their own 4 months postintervention (Fig 3).

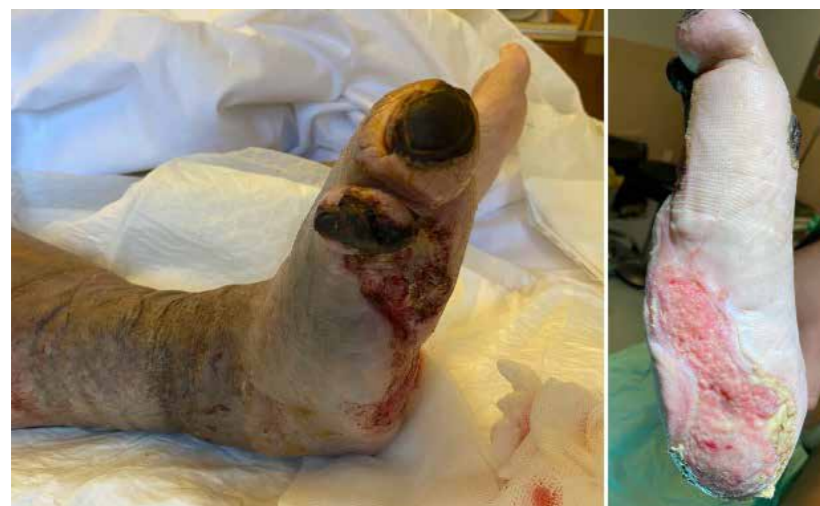

Fig 1. Severe diabetic foot syndrome at the time of admission

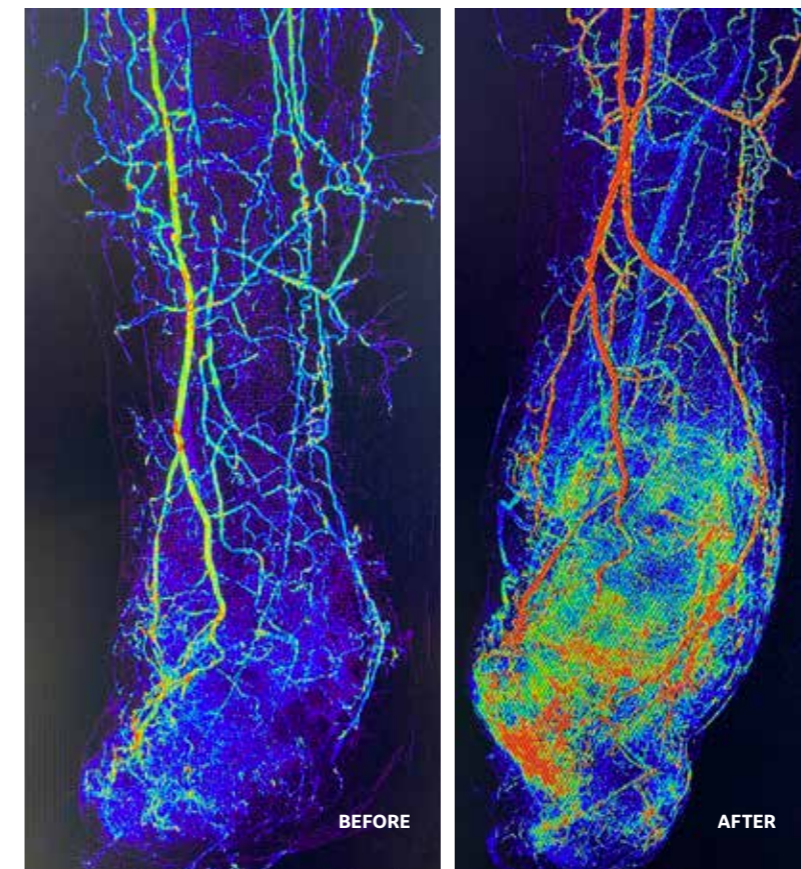


Fig 2. Pre- and postoperative perfusion as this is demonstrated by the AngioViz<sup>5</sup> software of the Discovery IGS 7

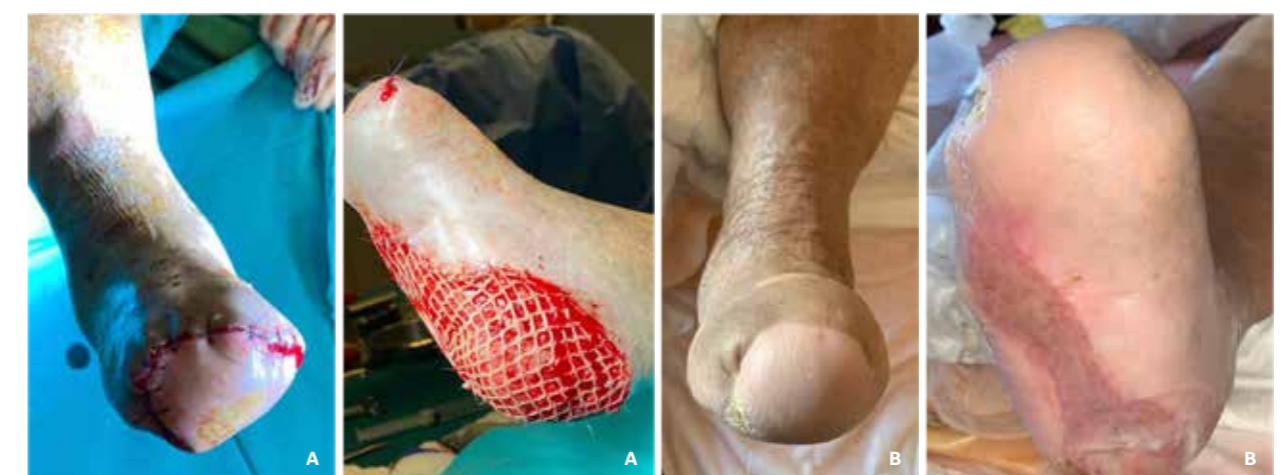

Fig 3. Clinical status of the forefoot directly after revascularization (A) and after 4 months of surveillance (B)

The statements by GE's customers described here are based on their own opinions and on results that were achieved in the customer's unique setting. Since there is no "typical" hospital and many variables exist, i.e. hospital size, case mix, etc., there can be no guarantee that other customers will achieve the same results.

5 AngioViz requires AW workstation. This application is sold separately.

# What can a hybrid room offer to the field of pulmonology?

## Reggio Emilia, Italy.

In 2016 in Reggio Emilia, Italy a new oncologic and hematologic center called CORE (Centro Oncologico ed Ematologico Reggio Emilia) was inaugurated as part of the main hospital Arcispedale Santa Maria Nuova. CORE is not only a highly specialized medical and research structure, but also a department specifically designed for the overall patient care.

In the Gastroenterology and Digestive Endoscopy unit, thanks to the dedication of the department's director, there is a hybrid room, equipped with a Discovery IGS 7\*, since 2017.

The director's team regularly uses the system to perform endoscopic retrograde cholangiopancreatography (ERCP) cases and complex treatments of the biliary tract, pancreas, and bowel.

Thanks to the versatility of the system, multi-disciplinary teams can perform procedures comfortably with unobstructed access to patients. Once a week the system is also used by the vascular team to perform complex EVAR cases and endoleak treatments.

Both teams routinely use 3D fusion image guidance for their procedures. The Discovery IGS 7 is equipped with ASSIST solutions<sup>1</sup> which allow them to superimpose reconstructions of various anatomic structures (such as vessels, organs and tumors) from pre-operative examinations on top of the fluoroscopy.

Recently, another team started to think about how this technology could be applied to their procedures. The interventional pulmonology team under the direction of Dr. Nicola Facciolongo recently started to use the system for pulmonary nodule biopsies to evaluate the potential the Discovery IGS 7 could bring to their practice.



**Dr. Nicola Facciolongo**  
Director of the Pulmonology Unit at Azienda Unità Sanitaria Locale - IRCCS di Reggio Emilia, Italy

**Dr. Facciolongo** is the Director of the Pulmonology Unit and is a Professor at the specialized postgraduate school of Respiratory Disease at the University of Modena and Reggio Emilia. He has broad experience in all bronchoscopic and thoracoscopic techniques. He is a lecturer for the master's degree in Interventional Pulmonology at the University of Florence and at the University of Ancona. He is an expert in the treatment of patients affected by severe asthma with bronchial thermoplasty. He is the author of more than 70 scientific publications, 40 of which are dedicated to the diagnosis and treatment of lung cancer.



**Dr. Roberto Piro**  
Head of the Interventional Pulmonology Unit at Azienda Unità Sanitaria Locale - IRCCS di Reggio Emilia, Italy

**Dr. Roberto Piro** is a board certified Interventional Pulmonologist with broad experience in all bronchoscopic and thoracoscopic techniques. He trained as a resident at the Università degli Studi di Modena and Reggio Emilia then he obtained the second level master's degree in Interventional Pulmonology at the University of Florence. Dr. Piro's research focuses on the role of interventional pulmonology in the diagnosis and therapy of lung and pleural diseases. He has published over 40 papers and a book chapter.

### What do you use to perform pulmonary biopsies during your clinical routine practice? How did the idea of looking for new innovative solutions come up?

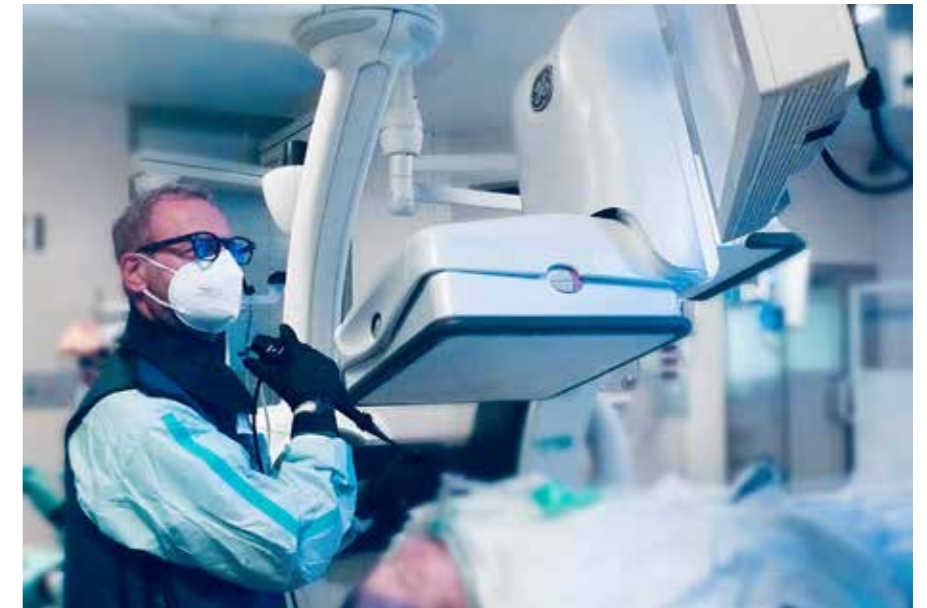**Dr. Piro:** For pulmonary biopsies we regularly use a C-arm image intensifier as a radiosopic guide together with a radial mini-probe, to search for the lesions inside the airways using ultrasound. This way, reaching the target is not always simple, particularly if the lesion is small and peripheral. Indeed, the smaller and more peripheral a lesion is, the harder it is to center the sampling device because the airway labyrinth gets you off track.

**Dr. Facciolongo:** We are searching for new navigation systems that let us, in combination with the radial probe and the ultra-slim bronchoscope, identify the nodules' position in an ever-more precise way.

At the moment several papers in literature define the use of C-arm and radial probe (and recently also the ultra-slim bronchoscope which allows to navigate more peripherally) as the best combination for a proper diagnostic definition while also remaining an economical option.

Nowadays electromagnetic navigation systems are also proposed as innovative solutions for these kinds of procedures, but they have not yet proved to be more beneficial compared to the traditional navigation techniques.

Electromagnetic navigators use a pre-operative CT that needs to be acquired just before the procedure. A 3D virtual reconstruction of the bronchial tree and target is performed



and then coupled (manually or automatically) with bronchoscopy images during the procedure. However, since the target and route are defined from a pre-operative acquisition, they can sometimes result in misleading information.

For these reasons we are looking for innovative solutions that could also allow us to reach small and peripheral lesions that we see ever more frequently and need a diagnosis before moving on to therapy.

### How did you get the idea to use the Discovery IGS 7?

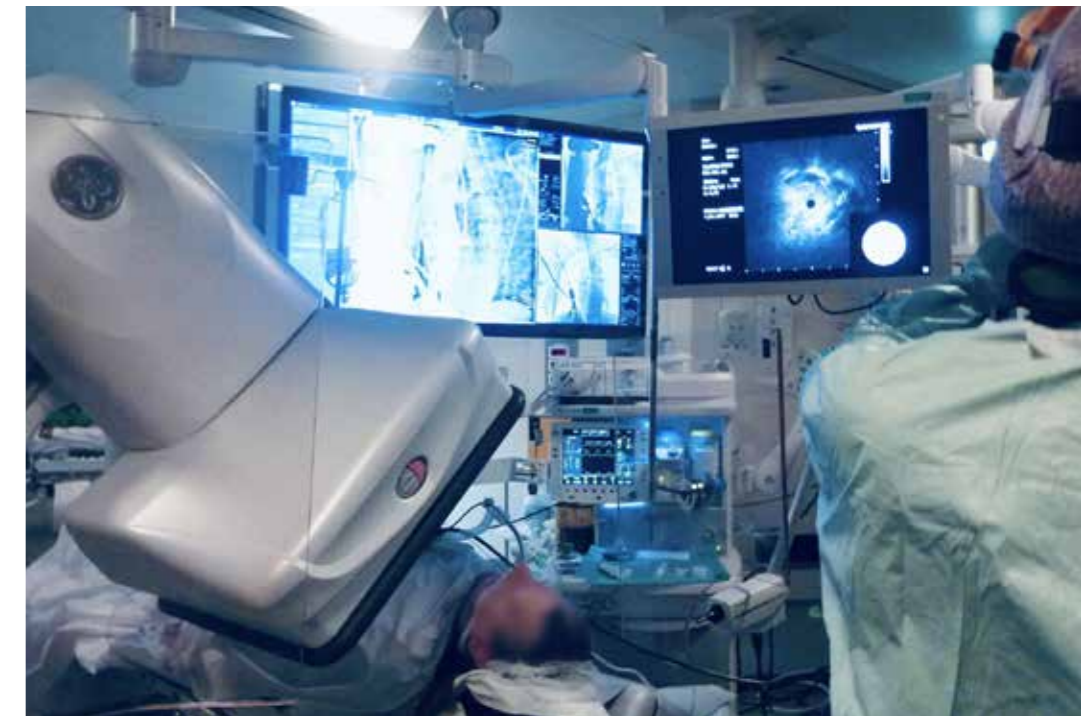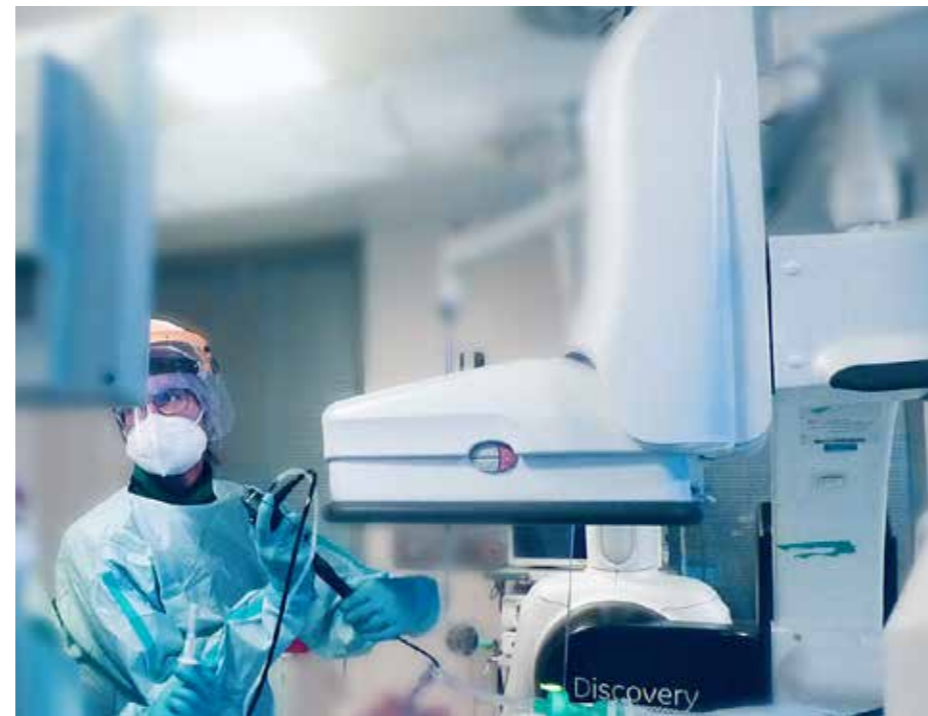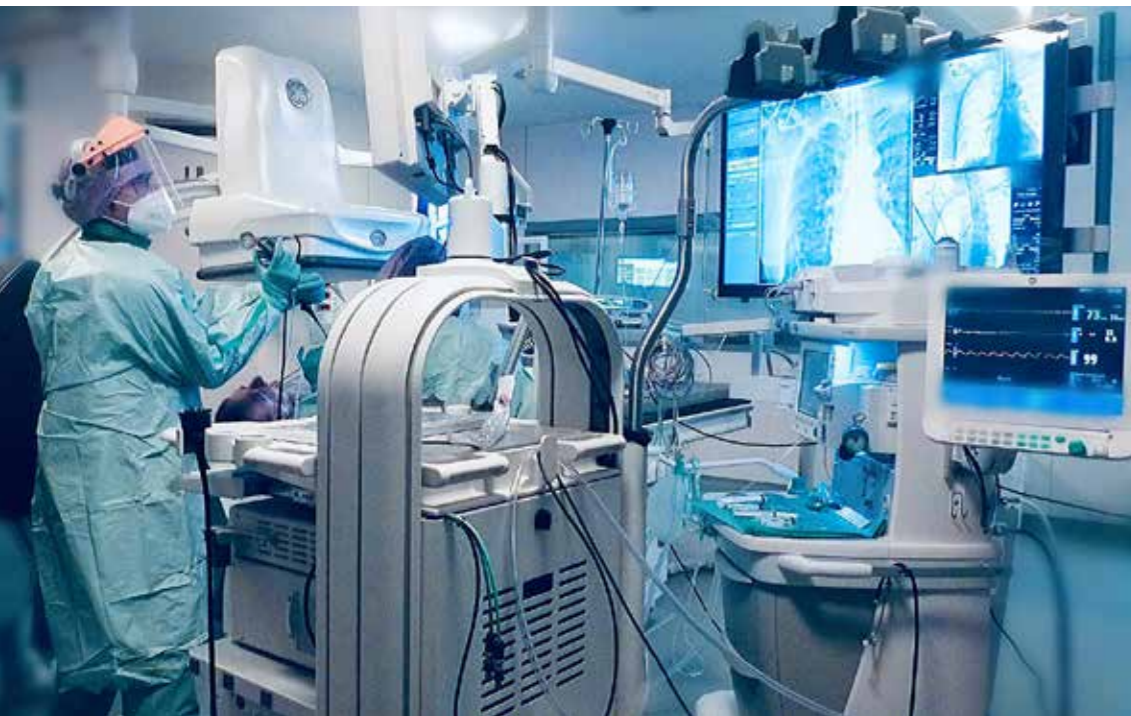**Dr. Facciolongo:** We knew about the Discovery IGS 7 at the Gastroenterology and Digestive Endoscopy unit of CORE, so we asked if we could work with this system in order to explore its capabilities, this time in the pulmonology field. They kindly responded positively to our request, so we performed some lung biopsy cases.

After these first cases, we understood that the Discovery IGS 7 has the ability to give us a precise definition of the nodule, and to identify a route to arrive accurately to the target and to proceed with the biopsy. All this in real time.

We know that at the moment we are only talking about a promising workflow that we need to re-evaluate after every case, but I find the starting point extremely interesting.

### What were the procedure steps?

**Dr. Facciolongo:** We are still standardizing a procedure workflow, but what we developed so far is the following: As soon as we are ready to start the procedure, we perform a Cone-Beam CT acquisition centering the chest of the patient who is positioned on the table of the Discovery IGS 7 system. The result of the CBCT is analyzed thanks to the Volume Viewer software. Two main volumes are reconstructed in 3D volume rendering and subsequently superimposed on the live fluoroscopy



thanks to the Vision 2 solution: the first one is the airways. These will give us the endobronchial route to reach or to get as close as possible to the nodule. The second one is the nodule itself, identified with a volumetric target. Since the volumes come from the CBCT, we do not need to do any registration step to match them with the fluoroscopy images. At this point, the bronchoscopy starts and the operator tries to reach the lesion while having a simultaneous view of both the bronchoscope and the 3D target on the fluoroscopy image. When the user thinks they have reached the target, a second assessment of the correct position of the target is performed via ultrasound using a radial probe. If confirmed, a reference is left inside the assumed target, which could be the radial probe itself or the needle/forceps we are going to use for the biopsy.

While keeping the reference in place, a second CBCT can be quickly performed to confirm once again if the reference is placed inside or close to the target.

If it confirms the result, we move to the sample collections, which could be done with a needle (when a bronchus path to arrive directly to the lesion does not exist) or with forceps (if we have a bronchus which arrives inside the lesion).

**What is your feedback for the use of the Discovery IGS 7? What are the main advantages?**

**Dr. Facciolongo:** Given that we have performed only a few cases, I believe that using the Discovery IGS 7 for our practice is very promising. The possibility to identify both the nodule and the bronchial route and superimpose them on the fluoroscopy

images represents really a key point for us compared to other traditional techniques. Doing a CBCT with a wide bore and a 40x40cm detector allows us to easily center the anatomy. Thanks to the CBCT we can have rapid results both in the initial phase, when we need to create the volumes for navigation, as well as during the intermediate steps, when we need to verify if we have reached the right location.

**What are the next steps now?**

**Dr. Piro:** The idea is to continue to perform pulmonary biopsies with the Discovery IGS 7, even with more complex cases, in the following months. We would like to standardize a workflow on a growing number of patients. For example, aside from some practical aspects of the procedure itself, we are evaluating the possibility

to perform the ROSE (Rapid on-site evaluation) directly in the hybrid room in order to know about the significance of the samples in real time. This way, if there is a presence of neoplastic cells we could keep collecting more samples from that or, if not, we could directly move to another area during the procedure.

Then, if there is good feedback for the diagnostic procedures during these months, we would also like to start performing therapeutic procedures.

When a diagnosis through endoscopy is not possible, in most cases patients go directly to surgery and the nodule

analysis is done after surgical removal. Some patients though, are quite fragile and such invasive procedures are not indicated. For them, new innovative therapeutic techniques such as ultrasounds, micro-waves, cryotherapy, etc are preferred. In order to offer this kind of therapy to our patients, we need to be able to get a secure diagnosis on the nodule under the guidance of endoscopic and fluoroscopic images, even more accurately than what is required for biopsies.

**Dr. Facciolongo:** Yes, the aim is to get to a correct diagnosis for the more difficult cases, in terms of dimensions

and localization. And this is essential not only before taking the patient into surgery, but also in the case of patients with comorbidities that can't be taken into the operating theatre. In their case, in order to proceed with treatment with chemotherapeutic and radiotherapeutic agents, having a previous exact diagnosis is fundamental.

In addition to that and focusing on timing, getting an accurate diagnosis as soon as possible is crucial, in particular for small nodules allowing for treatment at an early stage. □

The statements by GE's customers described here are based on their own opinions and on results that were achieved in the customer's unique setting. Since there is no "typical" hospital and many variables exist, i.e. hospital size, case mix, etc., there can be no guarantee that other customers will achieve the same results.

\*Discovery IGS 7, configuration 740

1 ASSIST solutions are composed of multiple medical devices. For more information, please refer to GEHC's website. [www.gehealthcare.com/assist](http://www.gehealthcare.com/assist)

# Lung biopsy using CBCT-based planning and guidance

Courtesy of Dr. Piro, Reggio Emilia Hospital, Italy

## Patient History

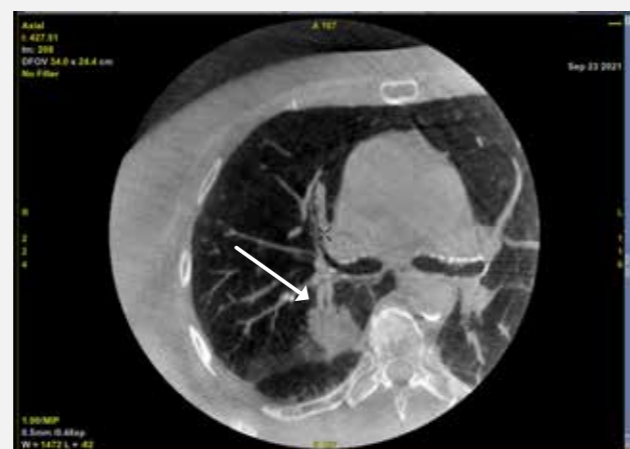Female, 76 y/o. In 2002 she underwent right hemicolectomy for adenocarcinoma (pT3N0M0), following adjuvant chemotherapy. In 2014 she received a diagnosis of squamous cell carcinoma of

the oropharynx (left tonsillar lodge) and she underwent concomitant RT-CHT treatment with radical intent. She is affected by a moderate COPD (FEV1 65% - TLC 119% - DLCO 49%). The CT scan of the chest performed in 2019 revealed a 15mm ground glass opacity in the upper

lobe of the right lung; it was followed up with CT scan and it remained stable until 2021, when it grew (27mm) and it presented a solid component of 9mm. PET showed a mild uptake of FDG (SUV max 1.7).

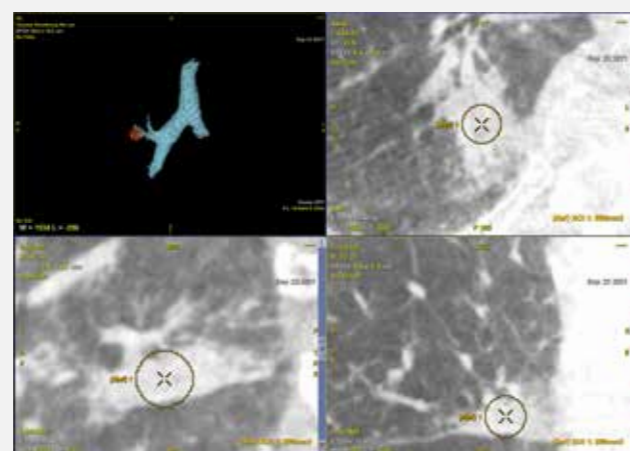
### Step 1 CBCT

40°/s - Dose limited protocol with Normal level of detail.  
The nodule's size appears larger than on the CT performed 2 months ago.



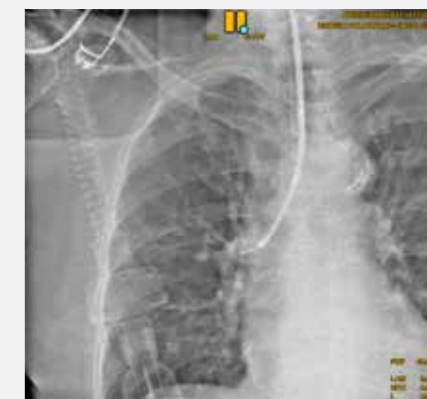### Step 2 Planning

The airways are segmented in a semi-automatic way on the CBCT. A target ROI (Region Of Interest) is placed on the nodule, underestimating its size in order to be closer to size estimation of the pre-op CT. The target is then converted into a volume and exported to Vision.

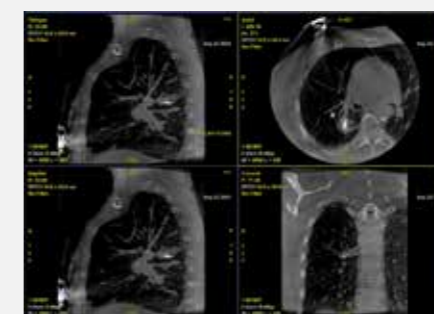


### Step 3 Guidance

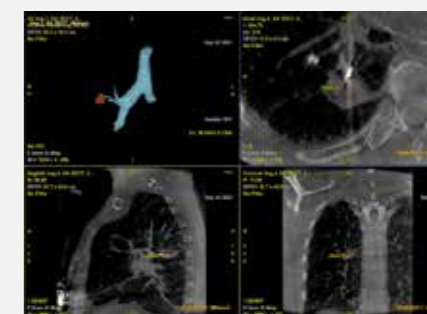
In Vision the target is superimposed on to the fluoroscopic images, allowing the operator to reach the lesion while having a simultaneous view of both the bronchoscope and the 3D target. A dose limited protocol at 7.5fps is used and for better visualization of the fluoroscopic images, an inversion of brightness and contrast values is performed.



### Step 4 Second CBCT and validation



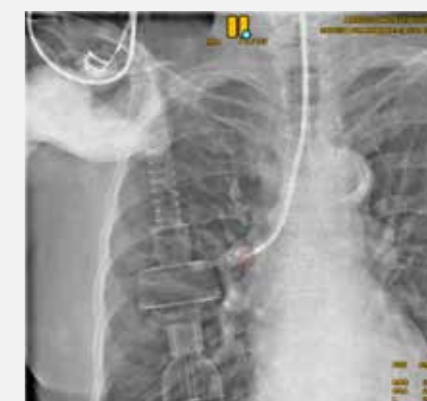Checking fluoroscopic images and the radial probe, once the target seems to have been reached, a second assessment is done using CBCT with a reference device (for example forceps) kept in place.



Superimposing the first CBCT target ROI with the second CBCT, shows the reference at the place of the target: the nodule has been reached.

### Step 5 Sample collections

3-5 samples are collected with forceps for histological analysis



#### Dose analysis

Total X-Ray time/Fluoro time	10.4/9.55 min
Dose	37mGy
DAP total/record/fluoro	15.15/11.93/3.22 Gy·cm <sup>2</sup>

The statements by GE's customers described here are based on their own opinions and on results that were achieved in the customer's unique setting. Since there is no "typical" hospital and many variables exist, i.e. hospital size, case mix, etc., there can be no guarantee that other customers will achieve the same results.

1 3D CT HD is an option sold separately. Includes 3DXR. Requires AW workstation and Volume Viewer. Available on Innova IGS 5, Innova IGS 6, Discovery IGS 7 and Discovery IGS 7 OR

# The cathlab that covers a third of Scotland with the latest Innova IGS 5 with AutoRight™<sup>1</sup>

The cardiology department of the Raigmore Hospital provides general cardiology care for all patients of the Highlands. In the only cathlab in the area, they predominantly perform angiograms, coronary interventions, stenting, and pacemaker implantations.





**Prof. Steve Leslie**  
Interventional  
cardiologist at  
Raigmore Hospital



**Dr. Jonathan Watt**  
Interventional  
cardiologist at  
Raigmore Hospital

**Rebecca MacLeod**  
Superintendent  
radiographer at  
Raigmore Hospital

### What challenges do you face in your hospital?

**SL:** NHS Highland covers a huge area, the size of Belgium, the size of Wales. Raigmore Hospital is situated at the south east corner of the region so patients have long travel times, with poor roads. So patients accessing the cathlab in an emergency situation can actually be challenging.

One of the ways to address these challenges is to make sure that our communication pre-hospital is optimal so we work extremely closely with the Scottish ambulance service and our coronary care nurses. We have a fairly robust pre-hospital ECG service where the ambulance service are encouraged to send all ECGs for symptomatic patients whether they've got ST elevation or not, so that we don't miss anybody and that we know about people who are potentially high risk, and allow them to be triaged to the cathlab as quickly as possible. The Scottish Ambulance Service have been

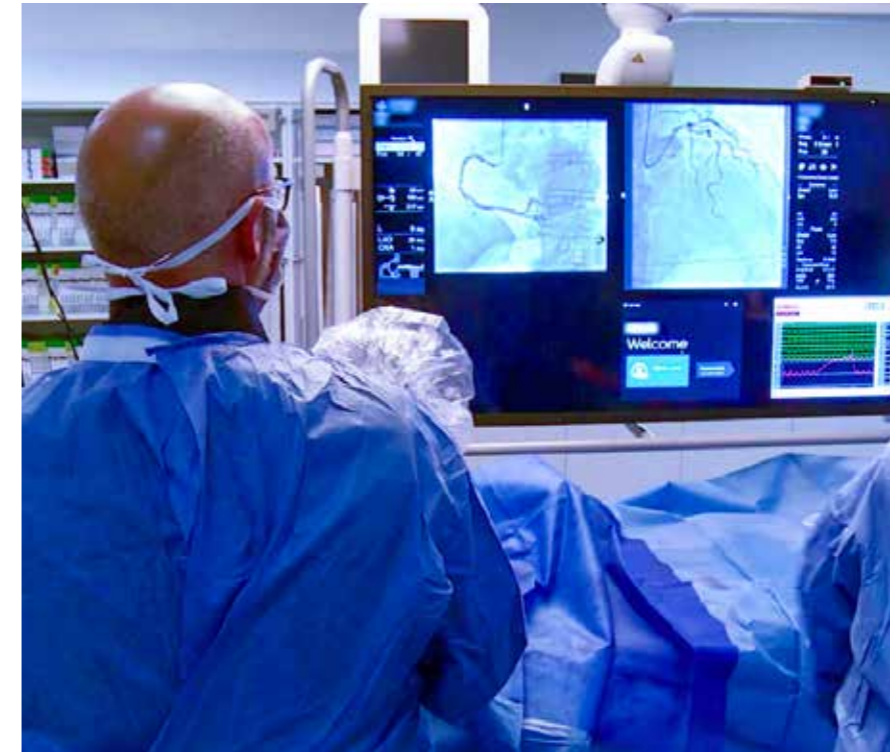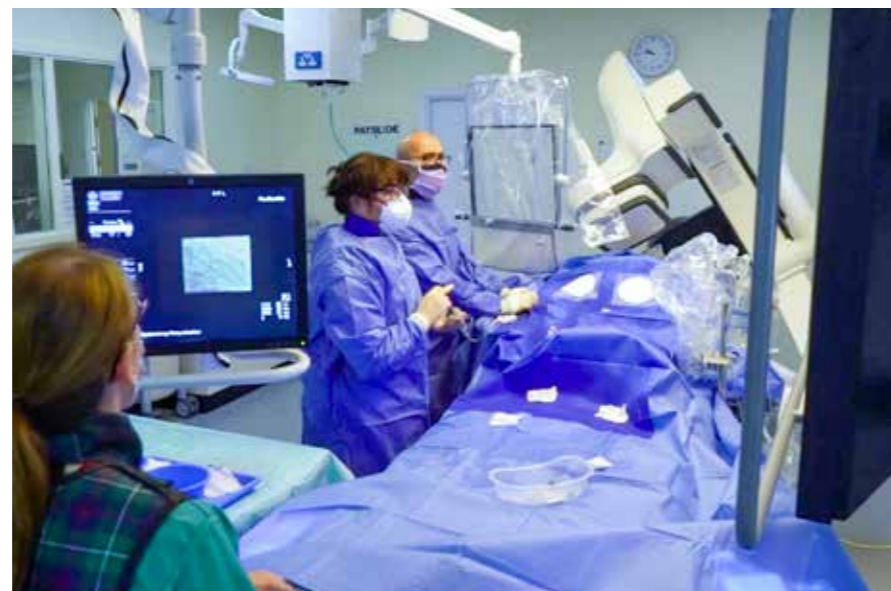fantastic and we receive over 3000 ECGs per year through our coronary care unit sent by email.

**JW:** We have got quite a remote geography here. So we have a very large catchment area, patients come from anywhere up to 100 miles away, and our nearest cathlab is really quite far away, two to three hours. Therefore, we need to be able to treat people here on site without having to rely on other sites. Reliability from the cathlab equipment is really very important.

### What do you think about AutoRight™<sup>1</sup> and the image quality?

**SL:** The Innova IGS 5 (configuration 520) with AutoRight™<sup>1</sup> gives us fantastic quality images. But more importantly it gives me confidence that the radiation exposure is as low and as optimised as it can be.

**RM:** Since our purchase of the new system with AutoRight™<sup>1</sup>, we have found that there has been a significant



dose reduction, specifically in long cases which previously would have had a very high dose. The image quality, especially with the large screen, has been fantastic.

Here in the Highlands, we have a very large proportion of the population that is prone to heart disease. When we need to do a long case, it is very difficult to get a good balance between image quality and dose. The new AutoRight™<sup>1</sup> system has made that a lot easier. It takes a lot of the guesswork out of the radiographers and lets them be assured that if they select the correct protocol, the radiation dose will be optimised for that patient. The radiographers are finding it very easy to use, it's been a very simple transition to move from the older generation lab to this one, and see those improvements really fast.

**JW:** AI plays a major role in the image chain at the present time. I think relying on humans to implement real-time changes in the cathlab is always going to be limited by training and time. Consequently, the more involvement from the device and the equipment, the better. I think automatization is going to be the future of dose optimization.

**RM:** The image quality has been fantastic in complex scenarios. The day this lab went live, we had two primary PCIs and the radiographers and the cardiologists had never been in the lab. It was a phenomenal achievement that the team felt confident enough to operate on those two patients without hiccup, with very good image quality and very good dose reduction.

### What do you think of third-party

### equipment integration in the cathlab?

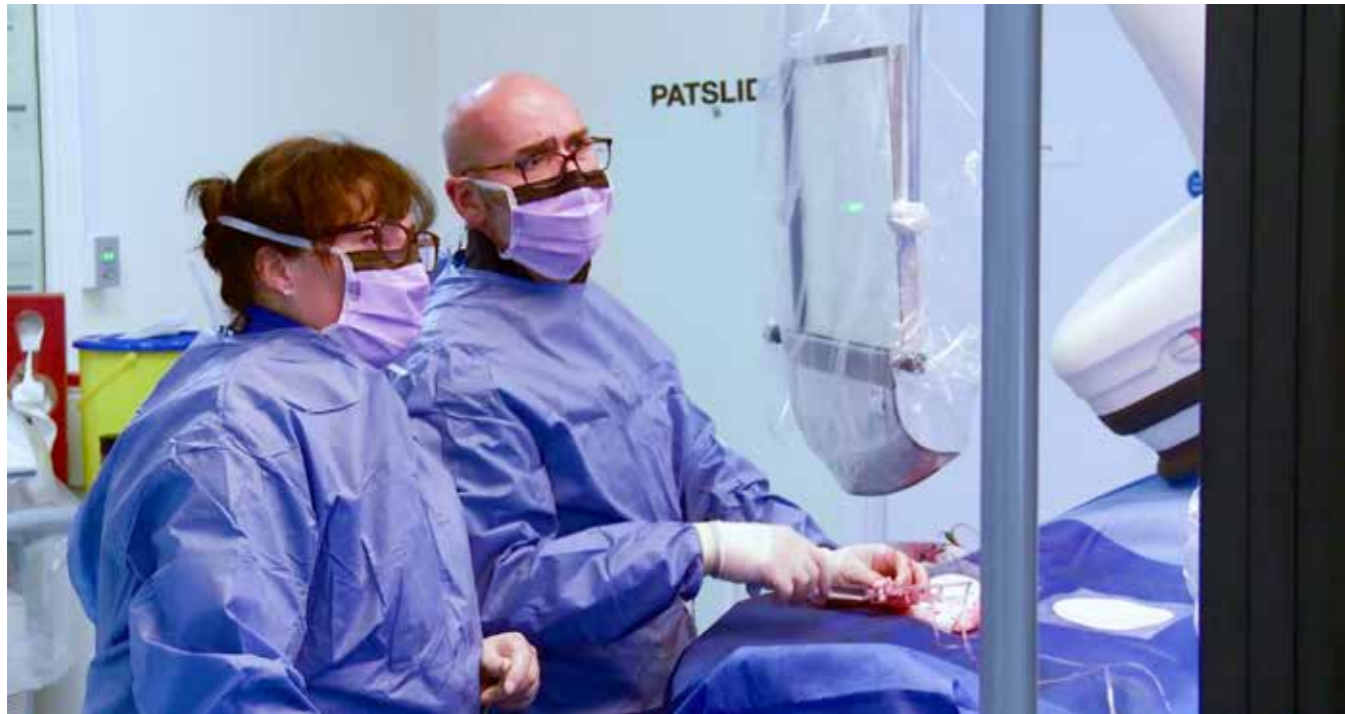**SL:** One of the great advantages of our new GEHC cathlab is the integration with third-party equipment. We can use OCT and IVUS very easily at the same case, to the best effect for the patient allowing them to have a safe angioplasty.

**JW:** The latest Innova IGS 5 cathlab integrates very well with the other modalities we have in the cathlab. These are very essential pieces of equipment allowing us to look at the coronary artery anatomy, including intravascular ultrasound and optical coherence tomography. We have a relatively high usage of these technologies in this cathlab, around 30 to 40%, which is significantly greater than many other UK centres performing PCI. We like to have easy access to the images on the same GEHC display. We have found that the workflow has been very much improved with the Innova IGS 5 system in order to provide immediate visualisation of the IVUS and OCT and coregistration with angiography.

### How do you use the improved StentViz<sup>2</sup> algorithm?

StentViz<sup>2</sup> is phenomenal. We are impressed at how quick it is to acquire and how quick it is to deliver the images. The image quality is absolutely phenomenal and I think that has been one of the biggest improvements for me.

**JW:** In the past, StentViz<sup>2</sup> was used only occasionally, now for most PCIs we use it routinely to ensure that we have good expansion of the stent but more importantly, to optimise the placement of the balloon to ensure the



stent is fully post-dilated. The image quality has improved, and more importantly the speed of processing the image has massively improved. The StentViz<sup>2</sup> picture is virtually instantaneous following the acquisition. Furthermore, the acquisition is automatically stopped after the required number of frames has been obtained.

**How do you feel supported by GEHC as a partner of choice?**

**SL:** GEHC were prompt with the build of the cathlab. It was fantastic to work with a company like GEHC, who did what they said they would do and completed the task on time.

**JW:** I think in this hospital it is really important to have a very close relationship with the company that provides the cathlab equipment. We have a long history with GEHC and they understand that we rely on them a lot because of our remoteness and our single cathlab. We require responsiveness from the company to provide repairs and servicing as soon as possible, because we are not able to access a second cardiac cathlab. So for us reliability and a service contract that works is something that is very important.

**RM:** We have always had a good working relationship with GEHC in the past, our previous lab was a GEHC lab

and everybody felt very comfortable with it. The GEHC choice was a perfect option because it allowed us to upgrade our existing system with very minimal build changes and training requirements. GEHC were brilliant at helping us source a GEHC mobile unit, which gave us a six-week bridge to allow our service to continue while the new lab was being installed.

We couldn't have been successful if the communication lines hadn't been that good, being in such a remote spot and having a lot of installation issues, simply because of location. Once you buy a piece of equipment like this, that support needs to be lifelong. □

The statements by GE's customers described here are based on their own opinions and on results that were achieved in the customer's unique setting. Since there is no "typical" hospital and many variables exist, i.e. hospital size, case mix, etc., there can be no guarantee that other customers will achieve the same results.

1 AutoRight refers to intelligent image chain features of GEHC's Interventional x-ray systems, from image acquisition to image processing and display, available on Innova IGS 5, Innova IGS 6, Discovery IGS 7, Discovery IGS 7 OR, Allia IGS 7 and Allia IGS 7 OR  
 2 StentViz is part of the PCI ASSIST solution



# CAPITALIZE ON ONLINE RESOURCES to facilitate training and increase your professional skills

The **GE CARES community** allows you to connect with other Healthcare professionals, share your experiences, publish content and learn new techniques by having direct access to clinical webinars, protocols and clinical cases to continually improve your skills. You can also contact GE Application Specialists whenever you need to ask a question or require support.



**LEARN**

Learn new techniques and increase your skills in your daily practice. Access online trainings, educational contents, clinical webinars built by experts for experts.



**CONNECT**

Connect with other healthcare professionals and grow your network. Interact with key opinion leaders and view their publications.



**SHARE**

Share your experience, publish content and stay up to date with the latest clinical trends shared by your peers.



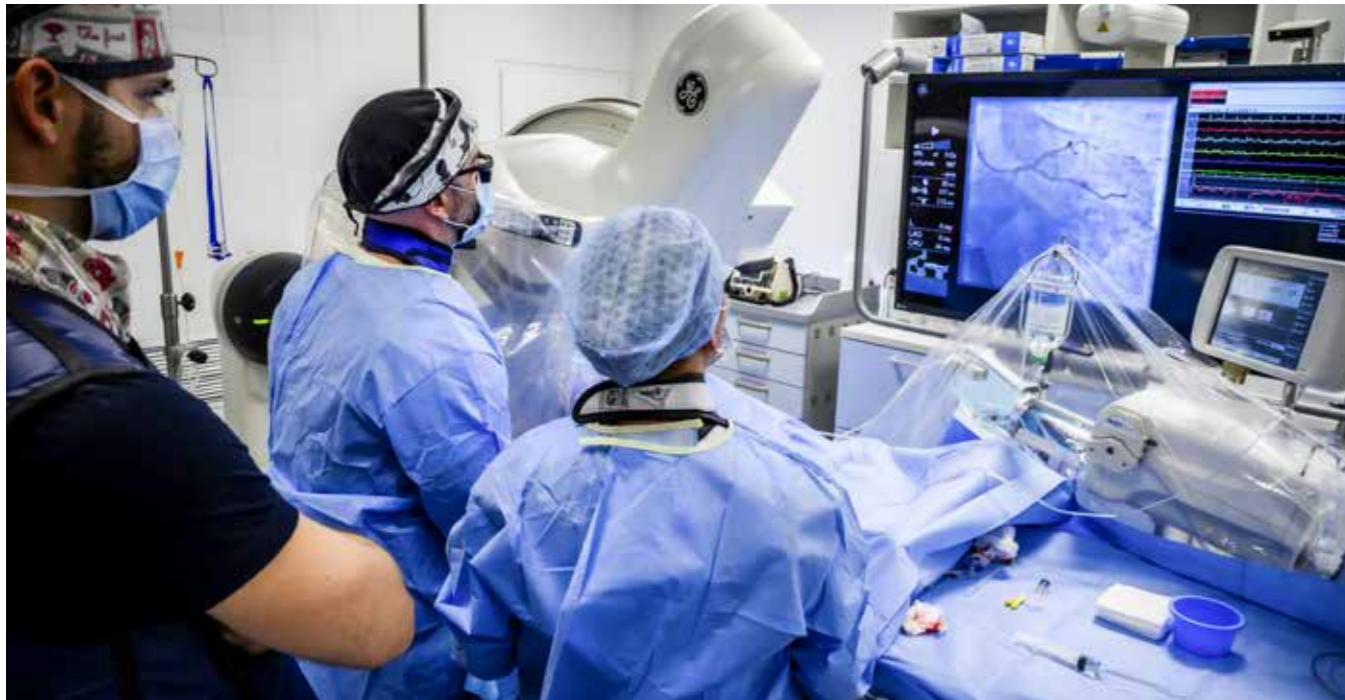# Exceeding expectations during a pandemic

The Heart and Vascular Center of Semmelweis University is a high volume center, performing about 3000 interventions, 300 TAVIs, Mitral clips, PFO and ASD closures per year.

Cases of Acute Coronary Syndrome in the vicinity of Budapest (3,000,000 people) are treated here on a 24-hour-basis on Wednesdays and Sundays and from 8AM to 6PM for the rest of the days.

It is one of two places in Hungary equipped to do mechanical circulation (ECMO) and be a Cardiac Shock Care Center (for Acute Cardiogenic Shock). The first ECMO was performed in 2012 and since 2017 the volume of cases has been increasing at a fast pace.

SEMMELWEIS



**How about the scientific work and education? Do you have any other ongoing expansion projects?**

**Prof. Merkely:** We made about 100 peer-reviewed publications and continued our “live” education program right after the first wave. We are just finishing up the expansion of our animal experimental lab (interventions, both on small and large animals) having tripled its capacity. We are also expanding our Cardiovascular OR section, and planning to have another Hybrid OR as well. We renewed our cathlabs with 1 replacement and 1

upgrade, so now we only see our images on “Widescreen”.

**What are you most proud of?**

**Prof. Merkely:** The fact that in spite of COVID-19, we were able to improve in several areas both scientifically and clinically and we were able to keep the live educational sessions going. We stepped up to the COVID-19 challenge and created the VV ECMO program by brainstorming about how to utilize our teams of cardiologists. So we did everything we usually do and much more.

**From the user’s point of view, how do you see the new Innova IGS 5 (configuration 520) cathlab from GEHC which you also regularly work on?**

**Prof. Merkely:** I like the fact that it has such a large screen, it helps me see the vessels in larger size and with better visibility. After the installation of the new Innova IGS 5 we decided to do the Large Display Monitor upgrade of the other Innova IGS 5 (configuration 530) as well.

We enjoy it, because it is also reliable, with low service maintenance. □



**Prof. Béla Merkely**  
Rector of Semmelweis University/Head of the Heart and Vascular Center

**Let’s start with the latest news: Semmelweis University became the 55th best higher education institution in the world (went up 32 places since last year) in the 2022 world rankings of the “US News Best Global Universities” in the “Cardiology and Cardiovascular System” category. Can you tell us a few words?**

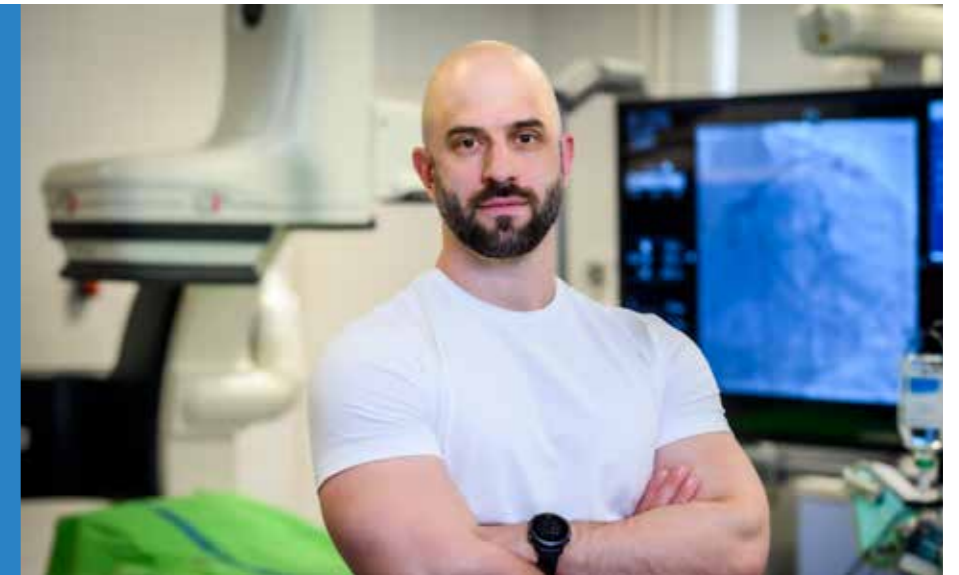**Prof. Merkely:** We are very glad about this improvement, and let me also interpret this result: Based on the numerical measurable parameters (e.g. citations) we are in 4th place, and only due to subjective criteria (such as reputation) we rank as 55th in total. So, with our actual performance we are in the top 20. We also extensively expanded our capabilities. In the year of COVID-19 we increased our Cardiosurgical activities, and Structural heart procedures by 40%

compared to 2019. The only drop we saw, of about 15%, was in infarcts (which is far better than what we’ve seen abroad, where patients stayed home and were not treated due to the pandemic).

We became a “Hybrid Institution”, treating both COVID and non-COVID patients. Based on the Performance Volume limit which is imposed by the country regulations, we were able to reach exactly 100% even though the expectations were set way before the pandemic hit.

We participated in COVID-19 testing, administration of vaccines, we even had patients on VV ECMO (we converted our VA ECMO program to suit their needs for lung support). Not to mention heart transplants, which we did about 40, although this number was smaller than usual due to fewer donors.

**Dr. István Édes**  
Head of the Hemodynamic department at Semmelweis University



**Can you tell me a few words about your team?**

**Dr. Édes:** Our team consists of mostly young doctors, but some of us have more than 10 years of experience, some with more than 20 years. I’ve been here for 14 years. Assistants are usually young, because our work stretches our limits and for this you need to be in good physical and psychological shape.

**Do you have a role in university education?**

**Dr. Édes:** All the time. Every day of the week medical students are coming to our labs from the different courses, speaking 3 languages (English, German and Hungarian).

**How did COVID change your routine?**

**Dr. Édes:** We were not a primary

COVID center, but people with COVID who needed urgent Cardiac Intervention were sent to us, since we were the only specialized cathlab who could handle such patients from all around the country due to our ECMO program (VA and VV).

**How many interventional cardiologists are in Hungary and what happened to them during the COVID pandemic?**

**Dr. Édes:** In total there are about 100 interventional cardiologists. This amounts to roughly 5 for each of the 20 labs, we have a few more.

The COVID pandemic is considered as “times of war”. Some of us got the “order” to serve in a different city. In this profession, under these circumstances, you need to realize you are a doctor, whose primary task is to save lives, whatever the conditions.

#### What are your daily PCI challenges?

**Dr. Édes:** The sheer number of patients. Our usual number was 40 patients per day, since COVID there has been a slight drop to about 30 per day for the 2 systems of the lab. This number represents only the elective, planned cases here, the acute cases come on top of it.

#### Which patients are the biggest challenge for this lab?

**Dr. Édes:** CHIPs (Complex Higher-risk and Indicated Patients), we get many of those from smaller labs and county hospitals. These are patients with poli-comorbidities, that cardiac surgeons don't want to treat, so our task is to save them.

#### What differences do you see between the old equipment and the new one?

**Dr. Édes:** The old machine has been here since 2006 and was replaced 14 years later. If we can name one medical device that has saved the most Hungarian lives in the country, it is this Innova 2100. This statement actually comes from Prof. Merkely, and it's undeniable. The new machine is incomparable with its gorgeous 58” screen. So much so, that we upgraded

the other Innova IGS 5 in the neighboring room with the same Large Display Monitor shortly after. The screen visibility and image size is crucial, because when we treat a COVID patient we have extra shielding (2 layers) in front of our eyes, so we need to see well enough through those layers. It's almost like you are working partially blind and deaf.

#### Do you take advantage of any other imaging systems, like Cardiac CT imaging?

**Dr. Édes:** Absolutely, we screen a lot of patients using CT before doing coronary angiographies. If the decision is to proceed to an intervention, we leverage the CT images for device sizing and planning. We have colleagues who do this full time, and we also learned to interpret the cardiac CT images ourselves in the cathlab.

#### What additional devices do you use to assist you in the procedure?

**Dr. Édes:** We have an emergency Ultrasound system, we use it to confirm the diagnosis. Intravascular imaging devices, and rotablaters are also available to us but are unfortunately not reimbursed by the National Health Fund.

#### What about the stent enhancement solutions?

**Dr. Édes:** We use them very often and like them very much, especially in the new machine with the combined contrast injection (StentVesselViz<sup>1</sup>). It displays such an accurate image that strut patterns are well visible and people who are truly familiar with these images (like me) can recognize the deployed stent type. A highly useful tool.

#### What about reliability?

**Dr. Édes:** These machines are heavily used 24/7 and regular service maintenance is a must. We do have a few breakdowns from time to time, but they have never happened at the same time on both machines. However, if that would ever happen, we still have a way out, because we have a total of 4 cathlabs (including our hybrid room and the periphery lab), so the ACS service will never cease.

#### What do you do about dose reduction? Is it a priority?

**Dr. Édes:** Absolutely. We use all tools that are available on top of what the machine is equipped with: radiation protection caps and spectacles, and even a “Ben-Hur”- style mobile shield. We installed electric leaded doors and the only people in the room are the ones who must be present for the procedure. We have taken a lot of exams on radiation safety and, personally, when teaching my young fellows, I put emphasis on how the operator can protect the nurses from radiation by correctly positioning the shields and the c-arm. It is also important that we are regularly monitored regarding our exposure. Regarding our patients, we've, thankfully, never had any dose-related accident until now.

Of course the fact that our system is now upgraded also helps, since the new algorithms can radically decrease the dose.

#### What about obese patients?

**Dr. Édes:** Just recently we had a patient like that. Not much to do in these cases, except for trying to see as much as possible to make the

intervention a success, even if in that case we need to use higher dose. The engineers optimize these machines to go as low as possible in terms of dose, and I also agree with this principle but when it is clinically needed we have to accept the higher levels of radiation.

#### Fluoro vs Record modes? Do you use Fluorostore?

**Dr. Édes:** Sometimes, and I should do this more often. However, I use the Fluoro mode at 7.5 frames, and during biopsies I use 3.75 frames, it is enough to guide the biopsy catheter to the right ventricle. I never use 30 fps for record, in my opinion if someone can't see with 15 fps, they should look for another profession.

I am not in favor of increasing framerates and dose at all. You may need to use higher dose, but if you

must, you should use collimation, zoom, and change angulation.

#### What would you like to achieve in 5 years?

**Dr. Édes:** To have enough money to work and have cost-efficient tools in our hands.

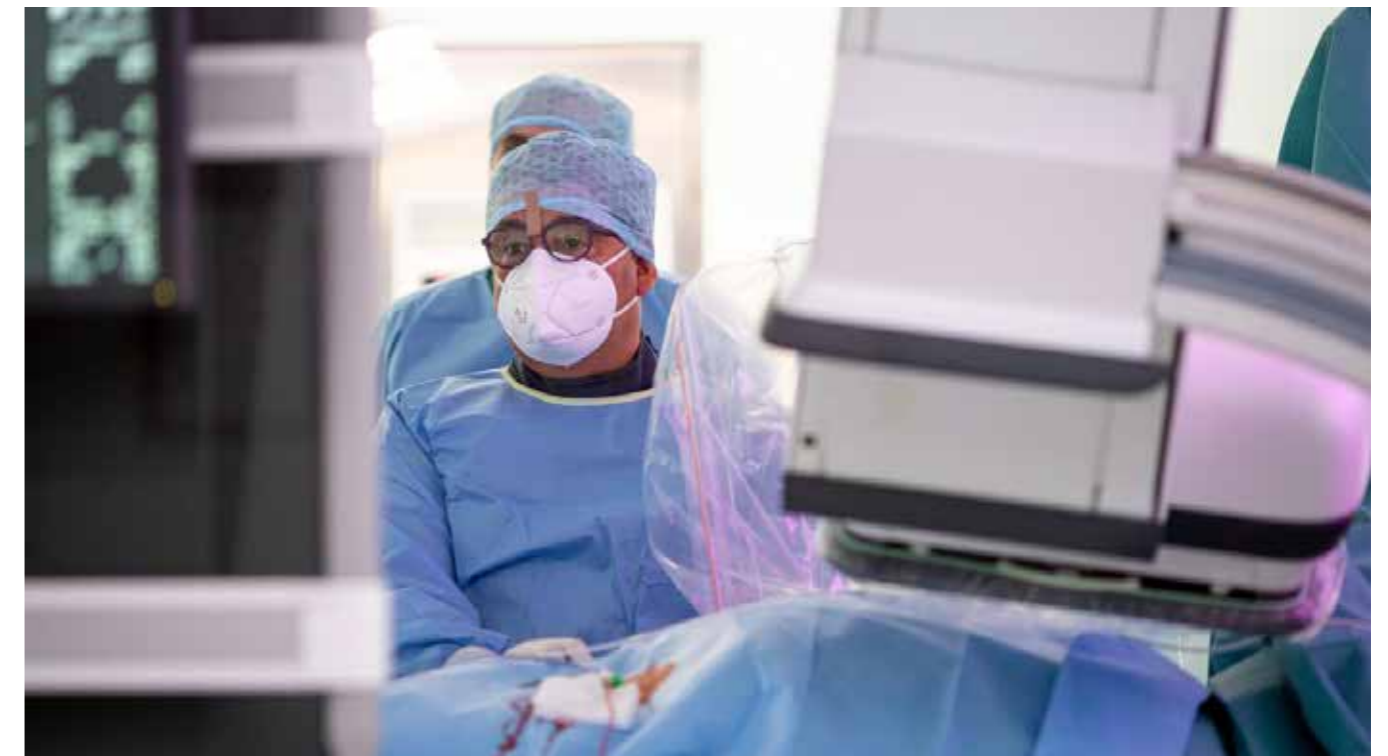When I studied in Germany, everyone was surprised when I was asking about the prices of the devices. There was no budget limit, no availability limitation there. The doctors' role there was to heal the patient regardless of the choice of the devices they used. In Hungary we need to be very careful with the device selection due to the reimbursement system. You can blow your costs up easily, by selecting a more expensive balloon, if it is not absolutely necessary. The whole clinic was built upon the Cathlabs and ACS

treatments. Simply put, our department finances the clinic, the Hemodynamics department is the workhorse, the moneymaker.

So I tell my colleagues to focus on using the most reliable tools (which may not be the most sophisticated ones, or the most expensive).

Having said this, in our lab we do have access to the latest tools (from rotablaters, to OCT and IVUS), and the widest consumable portfolio possible. We deliberately want to keep up competition among vendors with a free market approach.

The clinician has a wide range of choices and the final decision is up to them, even if for example they want to use Intravascular Lithotripsy (which is not reimbursed by the National Health Fund either). □



**Dr. Balázs Németh**  
Resident  
Interventional  
Cardiologist



**How long have you been doing interventions and how long was your learning curve?**

**Dr. Németh:** I have been working here for 3 years, and I would say 100 PCIs would be a good learning curve for a young interventionist. I reached this in about 6 months working here. Now I can do medium-level cases (but not the most complex ones) and I am planning to reach full scale (rotablation, ECMO

etc.) in the next 2 years. My mentor is István Édes, and his mentor was Prof. Béla Merkely, so I am the 3rd generation of interventional cardiologists here at The Heart and Vascular Centre.

**How much did colleagues and nurses help you in your journey?**

**Dr. Németh:** Tremendously. Our experienced nurses are also a source of

great feedback and I deliberately asked them to help me grow in all cases.

**How do you see the “rise of machines” in the field of Intervention? Will robots take over your job?**

**Dr. Németh:** Robots can be even better at doing the mechanical aspects, since their hands don't shake. But their intuition is not there yet, the clinical decision-making process is ultimately human during interventions. Challenging, borderline cases will not be solved by robots any time soon. These cases may account for about 5%, but it is still not negligible.

**Any observations about the dose?**

**Dr. Németh:** We noted with István that the dose levels were a lot lower than with the old Innova 2100 after we started using the new system. □



**Dr. Krisztina Heltai**  
Interventional  
Cardiologist

**There are not many female interventional cardiologists that I know of in the region. How does it feel working in a field full of men?**

**Dr. Heltai:** The problem is dominant men. In any profession it's hard for a woman when surrounded by men. We know that she needs to know more and work more for less income, the same applies for cathlabs, especially when the lab leaders and institute heads are also dominant men. As for me, I am not special because I am a woman, but because I started relatively late, at age 44, and this is not typical. Today you either start early, like Dr Németh or not at all.

**Did you have any challenges as a woman in this particular lab?**

**Dr. Heltai:** I am such an outlier (due to both my gender and my seniority) that I don't have any difficulties anymore. Here, my difficulties are in the past because when I arrived I already had 8 years of experience in Interventional Cardiology.

**What are some clinical challenges you are facing?**

**Dr. Heltai:** For example, special congenital cases, for which a better and bigger monitor that we now have surely helps. Generally, our patient population is getting sicker as time passes. 15 years ago we had different kinds of people on the table than today. Basically, modern healthcare and cardiology is able to keep many people alive and we now get those sicker patients on the table who we

couldn't treat 15 years ago. These cases are definitely more challenging.

**What about patient compliance?**

**Dr. Heltai:** Hungarian patients are compliant, as long as you care for them and give them your attention

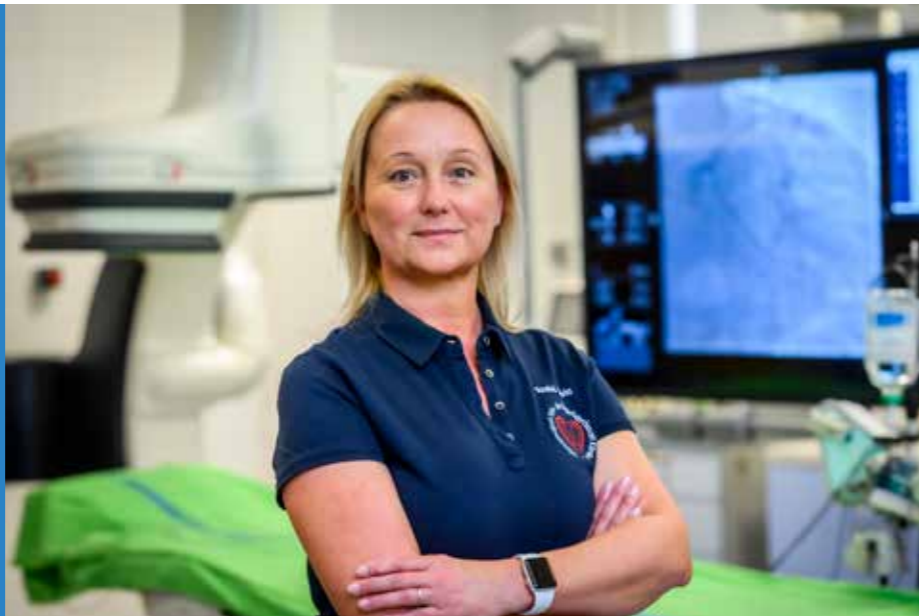**Do you use radial or femoral approach?**

**Dr. Heltai:** In my early days I actually learned femoral approach in 2009. But the world and the guidelines have changed, and today we use radial for at least 98% of the cases.

**Did the Innovalift campaign and machine installation go well?**

**Dr. Heltai:** It went according to plan, we got the machine on time, and we were able to manage the transition, because we already had experience from 2015 when the previous replacement happened. Regarding application training we also got strong support as usual from Jan Brutovsky (application specialist), we have direct contact with him, and we trust his expertise. □

**Szilvia Szabó**  
Head Nurse  
of the cathlab



**As a head nurse, are you the soul of this workplace? How long have you been in this position at The Heart and Vascular Centre?**

**Mrs. Szabó:** I came here 14 years ago, from Pécs University where I worked in the cathlab for 5 years.

**What do you consider your key traits or, in general, the key traits for a good nurse in the cathlab?**

**Mrs. Szabó:** Precision, attention, knowledge (including knowledge for the devices) and the ability to read the doctors' minds and support them with the right tools at the right moment. Obviously this takes a while (a few years for sure) to make all this automatic, but when that happens you will be able to predict the next steps in the procedure and see the potential outcome. That's how the team and yourself are always prepared.

**Would I be correct in saying, that the scope of a nurse's work may even be broader than that of the interventional cardiologist?**

Yes, it's true. Essentially the nurse is responsible for the patient from the moment they are booked for the exam, to the moment they leave the room. In the meantime, the nurse needs to coordinate the radiology technicians, the assistants, the orderlies, and to prepare the patient for the physician who will then be called only when the patient is fully prepared for catheter access.

A key focus area is to communicate with the patients, letting them know what awaits them has a calming effect. Some are nervous because they underwent other procedures before, some are nervous because they haven't. The nurse's task is to pay close attention to them.

For someone without a medical doctor's degree, being a nurse in the cathlab can serve as a unique career opportunity. There's tremendous professional growth opportunity, fast clinical developments, and serving next to a doctor saving lives you see your direct influence on people. It sure takes commitment, because it is hard work, but it's immensely satisfying.

**What is your opinion about the Innova IGS 5 system?**

**Mrs. Szabó:** I like it very much, it's speedy, and quick to position (especially the Innova IGS 5 with the cardiac table), the controls are easy and simple to use. We customized the programmable positions and we use them almost every time. If a doctor wants to deviate to steeper angles, obviously he can, but in most cases we just use the memorized setups.

**How do you see the relationship between Interventional Cardiologists and Cardiac Surgeons?**

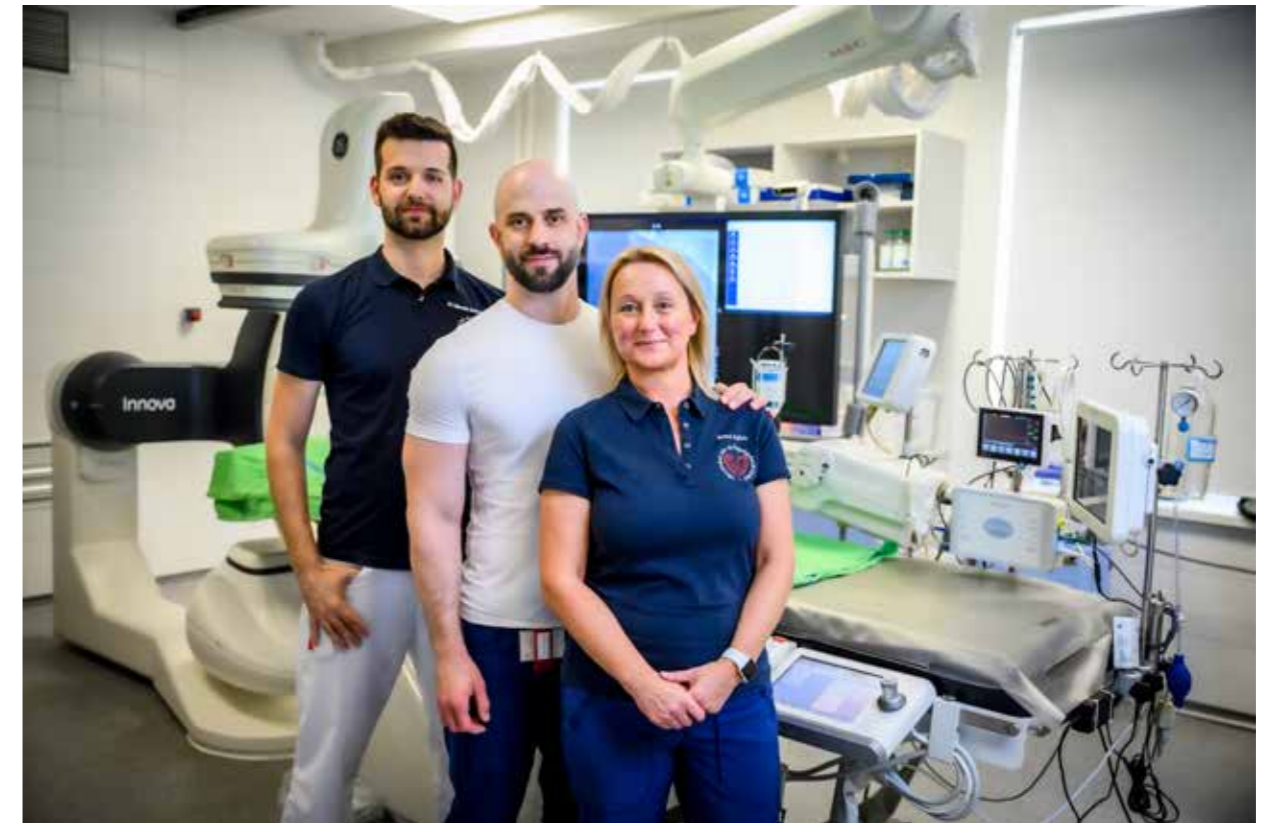**Mrs. Szabó:** Nowadays Interventional Cardiologists dare to go to places with catheters (like Left main) where only Cardiac Surgeons were going before with open procedures. The clinical range is definitely widening for us, both with the help of new tools and the validated endovascular practices.

However, we don't take on every case. We regularly hold cardiac/heart team meetings with the surgeons and decide about all questionable cases through a regulated process, and hand over the ones only suitable for surgery.

**Being an experienced nurse, are you involved in the clinical decision making?**

**Mrs. Szabó:** Interestingly, the answer is "yes", we are being asked for our

opinion in many situations. This is mainly because of our seniority and our expertise. These acts naturally balance out the long and hard hours on the job. We have a vocation, a calling and our passion is keeping us on track. □



The statements by GE's customers described here are based on their own opinions and on results that were achieved in the customer's unique setting. Since there is no "typical" hospital and many variables exist, i.e. hospital size, case mix, etc., there can be no guarantee that other customers will achieve the same results.

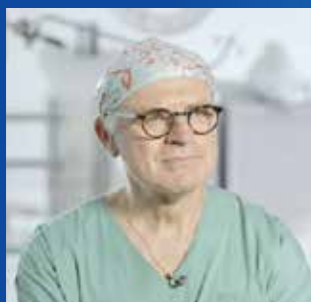1 StentVesselViz is part of the PCI ASSIST solution

# Leveraging technology for complex PCI procedures

## Pasteur clinic, Toulouse, France.

Clinique Pasteur in Toulouse (France), has this new building called La Passerelle - The Bridge. Designed by and for caregivers, all necessary services have been built & organized under one roof. Equipped with an arsenal of high tech imaging modalities dedicated to complex cardiovascular treatments, it aims at optimizing the care of cardiology patients.





**Dr. Bruno Farah** is an interventional cardiologist at the Pasteur clinic in Toulouse, France. His interests include coronaries, valves and PFO closures. He is also very interested in clinical research and has participated in various studies for devices and pharmaceuticals in the field of interventional cardiology.

**What type of procedures do you do?**

Most of my procedures are PCI, especially complex PCI and some structural heart procedures like PFO closure or LAA closure.

**Regarding PCI procedures, what kind of challenges do you face with your imaging system?**

What we need is to have a very good image quality because it's important to make the right decision about how we will treat the patient but also to evaluate the final result, especially the long-term result. So the image quality is really crucial. Also what we try to do is to have the best image quality at the lowest dose in order to reduce radiation exposure for the patient, the staff and myself.

**How do imaging systems help you with such procedures?**

In our Cathlab we have an Innova IGS 5 (configuration 520) and it helps us a lot in order to carefully evaluate the anatomy of the patient and the severity of the lesion and to make the correct decision: surgery versus PCI. Once we have decided to treat the patient with PCI, during the procedure,

it helps us to be sure that we are at the correct place, that we have a good deployment of the stent and finally that we have a good final angiographic image, necessary for a good long-term result.

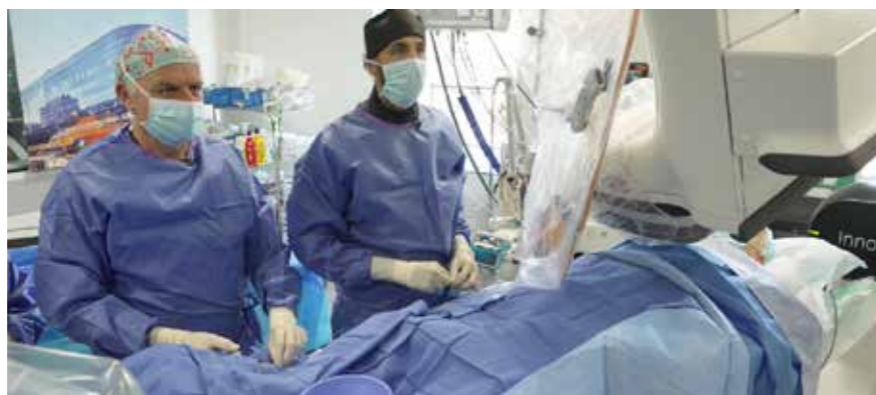**Do you often use stent enhancement software such as StentViz<sup>1</sup>?**

We use StentViz<sup>1</sup> quite routinely now. When using this software, we can be sure that the stent is correctly deployed without any shortening or deformation. Besides, since we are not using intra-coronary imaging for all the procedures, we use StentViz<sup>1</sup> as a secondary confirmation of the angiographic result before the final

angiography.

**What does the new StentViz<sup>1</sup> software bring to your practice when working on bifurcations?**

We started our experience with this new StentViz<sup>1</sup> software on bifurcations a few months ago. Clearly this gives you an advantage when you have to treat a bifurcation with two stents. First, it can help you to precisely position the second stent at the level of the carina when you do a TAP or a T stenting. Then, when you have the two stents deployed, StentViz<sup>1</sup> allows you to simultaneously evaluate the apposition and the deployment of the two stents and to clearly see what is happening at the level of the carina. □

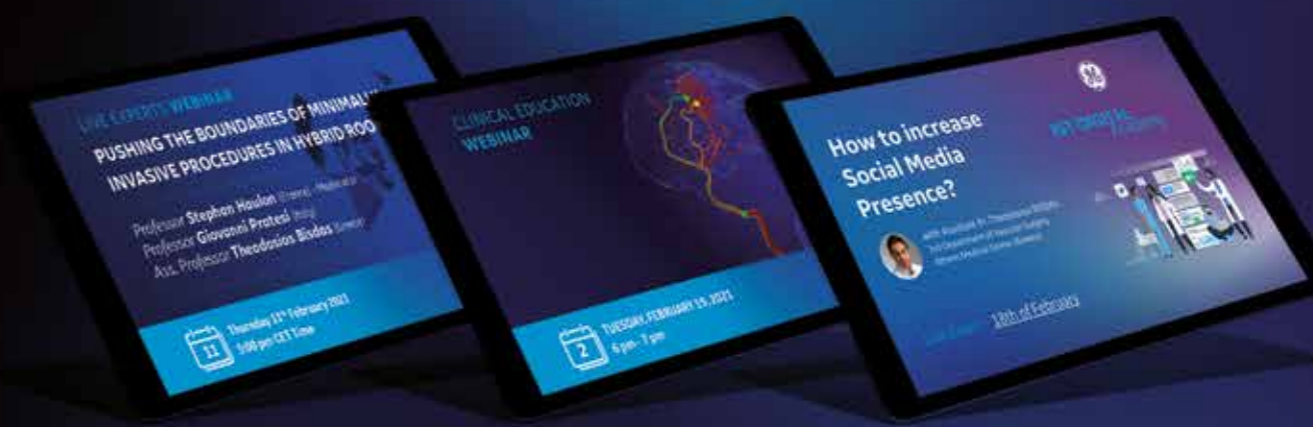

The statements by GE's customers described here are based on their own opinions and on results that were achieved in the customer's unique setting. Since there is no "typical" hospital and many variables exist, i.e. hospital size, case mix, etc., there can be no guarantee that other customers will achieve the same results.

1 StentViz is part of the PCI ASSIST solution



# EDUCATION HIGHLIGHTS AVAILABLE ON GECARES.COM



## Live Experts WEBINARS

- > Pushing the boundaries of minimally invasive procedures in hybrid rooms
- > How to increase your Social Media Presence?

## Clinical Education WEBINARS

- > Embo ASSIST: One stop shop for embolisations
- > "Untangling" arteriovenous malformations
- > Needle procedures: accurately and with minimum dose



# StentViz<sup>1</sup> for accurate bifurcation stenting

Courtesy of Dr. Farah, Pasteur clinic, Toulouse, France

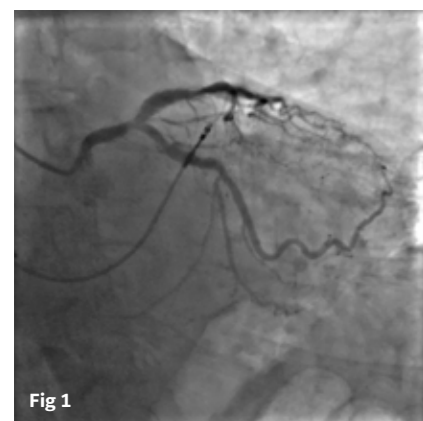


Fig 1

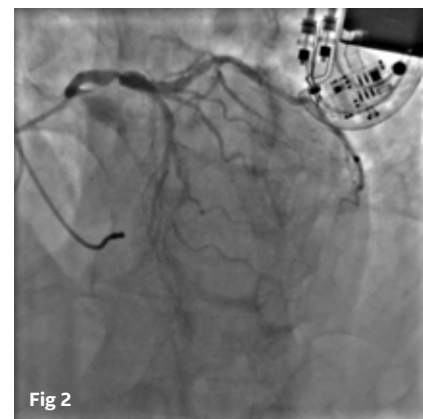


Fig 2

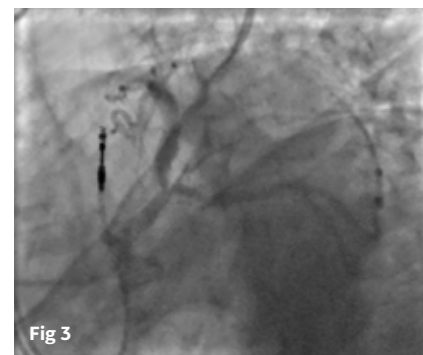


Fig 3

## Patient History

The patient is a 76-year-old male with normal weight.  
Risk factor: blood pressure and dyslipidemia.  
Previous history: pacemaker in 2006 and a prostatic cancer that has no evolution.

This patient was referred due to silent ischemia with a positive stress test especially in the anterior and lateral wall with an ejection fraction slowly decreasing during exertion. Blood tests, ECG and LV function are normal.

## The Decision Process

On the baseline angiography (Fig. 1) we can see that there is a calcified lesion at the level of the distal left main involving the LAD and the left circumflex. This tight lesion is more visible on the cranial view (Fig. 2). Finally in the spider view (Fig. 3), we see a true 1,1,1 bifurcation lesion involving the proximal LAD and the left circumflex. The right coronary artery is dominant without any significant disease, the patient has no other comorbidity and the risk evaluation is quite low (EuroSCORE of 1.25 %). The angiographic SYNTAX score is 13 and so, based on SYNTAX score II that provides a treatment recommendation between PCI and CABG, treating this patient with an angioplasty is a clear decision.

## The Procedure

Key objectives of the case: Treatment of the distal left main bifurcation with two drug-eluting stents using the TAP technique and the StentViz<sup>1</sup> software.

### 1. Deployment of the first stent.

We can see here (Fig. 4) result of the StentViz<sup>1</sup> for the positioning of the first stent. We have a very nice deployment of the stent at the level of the left main. Probably on the proximal LAD there is a small under-deployment but it's very calcified. We could go back with a non-compliant 4.0mm balloon afterwards. Clearly, we have a good result on the LAD.

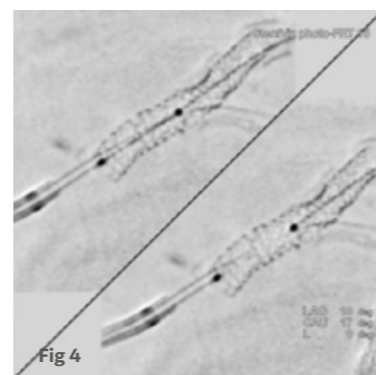


Fig 4

### 2. Positioning of the second stent

We use StentViz<sup>1</sup> to clearly see the stent at the level of the carina and correctly position it. We have a 3.50/16 stent at the level of the ostium of the circumflex. We have a 4.0mm balloon at the level of the LAD

and the challenge is to make sure that the proximal part of the left circumflex stent is just at the level of the carina without too much protrusion inside the left main but also without leaving a gap at the level of the ostium of the circumflex.

In this StentViz<sup>1</sup> acquisition (Fig. 5) we see the gap and we have to pull the stent back a little bit.

After that, the acquisition depicted in Fig. 6 shows a minimal protrusion.

### 3. Deployment of the second stent

After the deployment of the second stent we use StentViz<sup>1</sup> to evaluate the result at the level of the bifurcation. Looking at Fig. 7, first, we see good apposition of the two stents at the level of the left main - LAD and the level of the ostium of the circumflex. Second, we see that the stent position at the level of the carina of the left circumflex is satisfying. Finally, the stent at the ostium of the left main has no crush. So with this technology we can have the information about the left main, the LAD stent, the left circumflex stent and the position at the level of the carina.

### 4. Angiographic control

Looking at Fig. 8a, 8b, the result is good, you can see the neocarina. There is no disease or gap between the two stents. No distal dissection on the LAD or the circumflex.

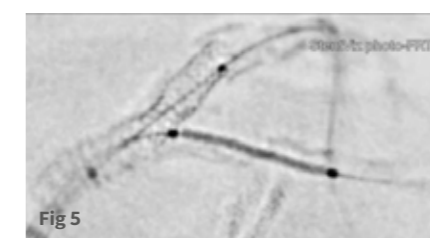


Fig 5

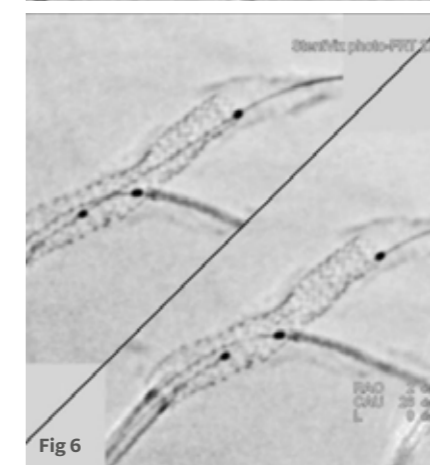


Fig 6

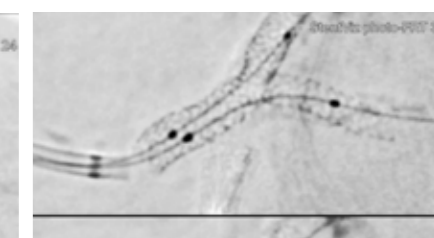


Fig 7

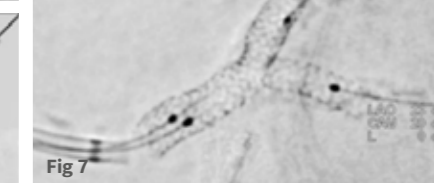


Fig 7

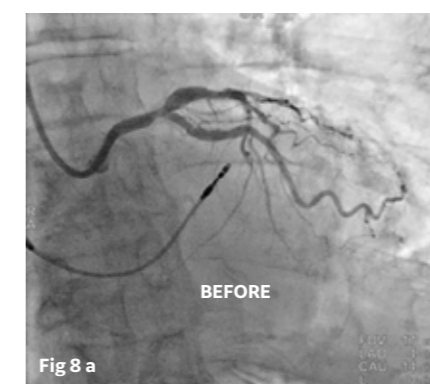


Fig 8 a

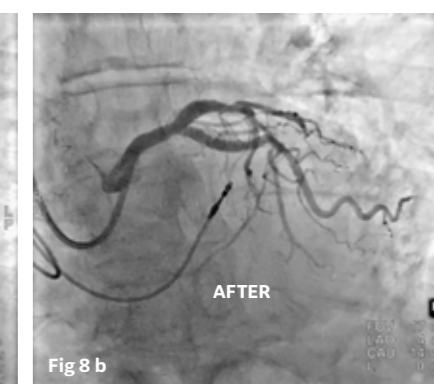


Fig 8 b

Flash this code to access the full live case from Dr Farah



The statements by GE's customers described here are based on their own opinions and on results that were achieved in the customer's unique setting. Since there is no "typical" hospital and many variables exist, i.e. hospital size, case mix, etc., there can be no guarantee that other customers will achieve the same results.

1 StentViz is part of the PCI ASSIST solution



## GE Healthcare

GE Healthcare provides medical technologies and services to help solve the challenges facing healthcare providers around the world. From medical imaging, software, patient monitoring and diagnostics, to biopharmaceutical manufacturing technologies, GE Healthcare solutions are designed to help healthcare professionals deliver better, more efficient and more effective outcomes for more patients.

GE Healthcare is betting big on digital; not just connecting hospital departments and physicians more effectively, but utilizing the masses of data from its equipment and the collaboration between hardware and software – “digital industrial” – to help clinicians make better care decisions. Sensors, software and smart data analytics are converging to enhance GE Healthcare’s offerings not just in diagnostics, but also pathology, gene sequencing and even hospital asset tracking.

GE interventional imaging systems help you plan, guide and assess your wide range of interventional procedures precisely and efficiently. The new generation of ASSIST advanced applications allow you to extend your clinical capabilities and help simplify and streamline your procedural workflow.

[Gehealthcare.com/ASSISTInterventional](https://www.gehealthcare.com/ASSISTInterventional)